DOES NOT CIRCULATE

UNIVERSITY OF MICHIGAN
1955
MEDICAL

VOLUME LXV JULY, 1955 NUMBER 7

THE LARYNGOSCOPE

UNIVERSITY

FOUNDED IN 1896
BY
MAX A. GOLDSTEIN, M.D.

PUBLISHED BY
THE LARYNGOSCOPE
40 SOUTH KINGSHIGHWAY ST. LOUIS (10), MO., U.S.A.

If your patient is HARD-OF-HEARING he needs three things...

1. ***A hearing aid*** **suited to his particular type of deafness. SONOTONE has many models—one of them will** ***help him to hear better.***

2. ***Friendly guidance*** **in choosing his aid and in teaching him to use it. SONOTONE Consultants have the training and the experience to help him.**

3. ***Uninterrupted hearing.*** **If his hearing aid doesn't work—whatever the reason—the consequences may be serious. No matter where he purchased his SONOTONE, he received with it a guarantee of uninterrupted hearing—renewable annually at a reasonable fee. Any SONOTONE office will honor this guarantee, including on-the-spot adjustments and repairs.** ***He walks out hearing.***

If your patient has a hearing aid problem suggest he see SONOTONE first. SONOTONE has over 400 of its own offices in the United States. One of them is reasonably near you. Consult the telephone directory for the address or write Dept. L-75, Sonotone Corporation, Elmsford, N. Y.

SONOTONE

A Lifetime Program for Better Hearing

rantee,
repairs.

em sug-
cas over
tes. One
the tele-
e Dept.
N. Y.

IE

aring

THE
LARYNGOSCOPE.

VOL. LXV JULY, 1955. No. 7

THE DEVELOPMENT OF THE EPITHELIUM OF THE LARYNX.*†

EUGENE S. HOPP, M.D.,
San Francisco, Calif.

What type of cell composes the mucous membrane of the larynx? Where is the epithelium squamous? Where is it ciliated? Does squamous epithelium occur in the areas of the larynx in which it is present because of a functional or pathological transition, or does it begin to differentiate in the embryo as part of an orderly process of development? These questions have interested and troubled every laryngologist. Investigation of present day histology textbooks reveals a considerable difference of opinion on the problem.

In the 1934 edition of his book Cowdry[3] stated that the upper part of the laryngeal vestibule is lined with stratified squamous epithelium, the lower part ciliated; over the vocal cords there is again squamous epithelium and again ciliated epithelium in the trachea.

Ten years later in a new edition of his book Cowdry[4] says only that the "mucous membrane resembles that of the pharynx." Maximow and Bloom[18] add nothing to the first description of Cowdry. Sometimes the description of the laryngeal epithelium is vague, *e.g.*, Sir E. Sharper-Schafer[20] states that over the true cords and epiglottis, "as well as here

* Presented as Candidate's Thesis at the Fifty-Ninth Annual Meeting of the American Laryngological, Rhinological and Otological Society, Inc., Hollywood, Fla., March 16, 1955.

† From the Sub-Department of Otorhinolaryngology, University of California School of Medicine, San Francisco, California.

Editor's Note: This ms. received in Laryngoscope Office and accepted for publication, March 23, 1955.

and there in the part of the larynx just above the glottis, stratified epithelium is found."

Bailey's[1] textbook tells little more: "The wall of the aperture of the larynx, including the epiglottis down nearly as far as its tubercle or cushion, is lined by stratified squamous epithelium. This is succeeded by the pseudostratified ciliated columnar type which lines the remainder of the laryngeal wall except for the vocal folds, which is of the stratified squamous variety."

In 1936 Bremer[2] wrote a more accurate and complete description of the laryngeal epithelium: "The mucous membrane of the larynx is a continuation of that of the pharynx . . . " "In most places the epithelium appears to be stratified, the top layer being either cuboidal or columnar. It may be pseudo-stratified . . . " "A stratified epithelium with squamous nonciliated outer cells is found on the vocal folds (true vocal cords), on the anterior surface of the arytenoid cartilages, and on the laryngeal surface of the epiglottis. The distribution of the two sorts of epithelium above the vocal folds is subject to individual variation. The squamous epithelium often occurs in islands and is said to replace the ciliated after local infectious desquamation." The last sentence is particularly worthy of study and will be referred to again.

More recently Ham[10] wrote another accurate description of the epithelium of the larynx: "The epithelium of the mucous membrane of the larynx varies in relation to the function performed by its different parts. That covering the true vocal cords, which are subjected to considerable wear and tear, is of the stratified squamous nonkeratinizing type. All the epithelium lining the larynx below the true vocal cords is of pseudostratified columnar ciliated type with goblet cells. Most of that lining the larynx above the vocal cords is also of this type although patches of stratified squamous nonkeratinizing epithelium may be present in some sites."

Greep's[9] histology, published in 1954, also subscribes to the function theory and speaks of stratified squamous epithelium on the upper half of the epiglottis, on its posterior surface, on the arytenoid cartilages and on the vocal cords. "These

are all exposed surfaces that are subject to some wear and tear."

Not all descriptions are completely accurate. In Jordan's[15] textbook we read that: "The upper portion of the larynx, including the greater part of the epiglottis as far as the false vocal cords, is lined with stratified squamous epithelium which is continuous with that of the pharynx."

Interest in the histology of the laryngeal mucosa is not new. The mucosal covering of the larynx was first mentioned in the writings of Galen[7] (131-201 A.D.). He was familiar with the ability of the membrane to secrete mucous.

With improvement of the microscope Jacob Henle,[12] a professor of anatomy at Zurich, proved in 1838, that the larynx had an epithelial covering which was ciliated. It remained for the period of the last two decades of the 19th Century for detailed studies of the laryngeal epithelium.

It is not until 1885 that an adequate description of the histology of the larynx can be found. Tourneux[23] determined that the free margin of the vocal cord was composed of stratified epithelium and that the rest of the adjacent area was covered by ciliated epithelium. In 1889 and 1890 there raged a controversy over whether the squamous epithelium of the larynx was the result of gradual differentiation from the embryo, or whether islands of squamous epithelium appeared because of functional or pathological change. The two protagonists were A. A. Kanthack[17] and Rudi Heymann.[14]

Kanthack was an Englishman working at the Pathological Institute in Berlin, and writing in German. He was a protege of Virchow. His treatise on the histology of the laryngeal mucosa is truly a fine, detailed work of three parts totaling 47 pages. It merits being reprinted in English today.

Kanthack described in the half-term fetus a ciliary epithelium and a stratified pavement or squamous epithelium, which at that stage had rather a cuboidal structure. The ciliated epithelium was found over a larger area of the fetal larynx than is the case in the adult. It was present on the entire laryngeal surface of the epiglottis and extended to the vocal cords. Since the ventricle was developed at this stage

it was also examined and found to be lined with "beautiful ciliated epithelium."

Kanthack endeavors to differentiate between what he calls "Pflaster" epithelium and "Platten" epithelium as two varieties of squamous lining. I have translated the "Pflaster" as pavement epithelium and the "Platten" as lamellar epithelium. I have consulted with many German scholars and referred to several German histology books, including Stohr's Lehrbuch der Histologie[22] and can find this distinction nowhere else.

By definition, however, Kanthack describes as "Pflaster," or pavement, epithelium that in which the cells fit together in a cuboidal or mosaic fashion; whereas in "Platten," or lamellar, epithelium the uppermost layers are distinctly flattened but not necessarily cornified. The area of the half-term fetal larynx which is covered with cuboid, or pavement, epithelium is only the true cord area. Kanthack states categorically that this epithelium "is found nowhere else." The entire *pars respiratoria* is covered with ciliated epithelium. In contrast with this pavement, or "Pflaster," epithelium that of the adult vocal cord is stratified lamellar or squamous epithelium (Platten), in which the upper layers often show distinct cornification.

Because of the anatomical arrangement of the vocal cord and the ventricle in the embryo, a small portion of the entrance of the ventricle is also covered with cuboidal epithelium. The transition from ciliated to cuboidal epithelium is abrupt superiorly, but may be more gradual below the cord. No papillae can be found in the fetal vocal cord. Kanthack states further that "it is doubtful, however, whether under normal conditions papillae are found in the adult." This statement my own studies and photomicrographs disprove.

In the newborn, Kanthack found the area of pavement epithelium very small as compared with the adult. It was a larger area, however, than that found in the half-term fetus. He described the pavement epithelium of the oral pharynx as reaching the tip of the epiglottis, and in some cases even extending down over the laryngeal surface. Usually the entire laryngeal surface of the epiglottis is covered with tall ciliated epithelium which extends over the false cords and down to

the true cords. The true cords are covered with pavement epithelium at the anterior commissure. It is fairly high, and gradually becomes lower towards the posterior edge of the cord. It extends to the region of the processus vocalis. As soon as it leaves the arytenoid the pavement epithelium ends and ciliated epithelium begins, and even covers the area of the posterior commissure. Although the pavement epithelium becomes lower from anterior to posterior, on the arytenoid inner surface it again becomes high, and is higher than anywhere else.

Heymann[14] in contrast to Kanthack described scattered islands of squamous epithelium in the larynx. He considered them to be normal occurrences, and believed that he could explain the situation on the basis of the embryonic history of the organism. Since the larynx lies, so to speak, at the junction of the airway lined with cylindrical epithelium and of the part of the tract lined with squamous epithelium, an intermingling of both types might occur; furthermore, Heymann subscribed to the demonstration of Ganghofner[6] that the larynx developed from two parts—one belonging to the trachea, the other the base of the tongue. He also described transitional forms between ciliated cylindrical epithelium and the pavement epithelium.

Kanthack felt that the islands of squamous epithelium described by Heymann were not physiological since they could not be found in the embryo. The islands of Heymann, occurring in the midst of ciliated epithelium, were due to pathological metaplasia, said Kanthack. He examined the larynges of two children who died during the first year of life and found the entire mucosa up to the lower margin of the true cords covered with pavement epithelium, and even found a similar change on the posterior surface of the epiglottis.

Further microscopic study of these larynges revealed evidences of inflammation, such as dilated vessels and leukocytic infiltration beneath the surface epithelium and between the muscle fibers. Kanthack compared the epithelial metaplasia in the larynx to that described in nasal polyps and in the mucous membrane of the stomach, bowel, gallbladder, uterus, urethra, trachea, and bronchi.

Kanthack was also able to demonstrate microscopically that in both syphilis and tuberculosis of the larynx so much squamous metaplasia sometimes occurred that the entire larynx became covered with a tough pavement epithelium. It was probably on the basis of these studies that Bremer[2] in his textbook noted, as I indicated above, that the "squamous epithelium is said to replace the ciliated after local infectious desquamation."

Many workers such as Semon,[19] Frankel,[6] and Kallius[16] added further embryo and adult larynx studies, but not until 1898 when Doctor P. Heymann[13] wrote a scholarly monograph on the histology of the mucosa of the larynx were any appreciable additions made to the understanding of the human laryngeal epithelium. Doctor Heymann wrote that the thickness of the mucosa was variable, not only from individual to individual, but from point to point; therefore, the various numerical diameters given by Henle[5c] and Luschka[5c] and others could have no very accurate significance.

Heymann also described the two completely different types of epithelium: the ciliated cylindrical epithelium and the stratified squamous epithelium. Since he found the layers of ciliated epithelium not clearly differentiated, he felt that the studies of Frankenhauser[5b] and others assuming the presence of two layers, and of Dolkowski[5a] and Kolliker[5d] assuming three layers could both be correct in different instances. Heymann further differentiated a deep layer of epithelium resting on a basement membrane formed of somewhat cuboidal shaped cells with large, round or oval nuclei and an upper layer of epithelium formed by ciliated cells interspersed with goblet cells. These latter were present in exceedingly variable numbers in five specimens.

It was noted that the length of the ciliated cells was variable, and that some of them probably did not reach to the basement membrane, or basement cell layer. The goblet cells were considered to be derived from ciliated cells. In the stratified squamous epithelium Heymann found that the deepest layer was very similar to the layer of basal cells of the ciliated epithelium. This basal layer was continuous with that of the basal layer of the ciliated epithelium, although the cells were

slightly more cylindrical. The thickness of the stratified squamous epithelium was also variable and depended upon the number of layers of the cells between the basement membrane and the more flattened surface cells.

Heymann further discusses the character of the squamous epithelium of the larynx and confirms the presence of papillae as the result of sections made in more than 70 human larynges. The papillae were parallel to the free border of the vocal cord and were not deeply indented as they normally are in the skin. As Heymann says, "They were not digit-like but trestle-like." To establish that these papillae were not pathologic formations as Kanthack and others maintained, Heymann described them in the larynx of the newborn, and Tourneux[23] described them in the larynx of an eight-day old child.

Heymann maintained that the trestle-like arrangement of the papillae on the vocal cords probably had a certain relationship to the function of the cords. "The stresses which befall the vocal cord in the course of its normal function are applied in general in a direction perpendicular to the long axis of the edges of the vocal cords. The longitudinal arrangement of the trestle-like papillae which serve as an anchoring and strengthening apparatus can best withstand the stresses applied in this direction."

From about 1910 onward, I could find no original study or research on the epithelium of the larynx in the human with the exception of one article by Vidoni,[24] in Italian, published in 1953. This excellent study was titled, "Sullo Sviluppo E Sull'istogenesi Del Labbro Vocale" (On the Development and Histogenesis of the Vocal Lips). Doctor Vidoni studied 25 fetuses ranging from the first weeks of uterine life to birth. His smallest fetus was one of 43 mm. which he described as from the eighth to ninth week of intrauterine life. He showed an excellent series of photographs of the external and internal appearance of the larynges of many of his fetuses.

Vidoni was concerned only with the vocal lips, and concluded that they were evident starting from the eighth week of intrauterine life and completely formed in fetuses 400 mm. long. Since the study was concerned with this area alone, the microscopic sections in his paper deal only with the vocal lips

and do not further differentiate the varying types of epithelium in the larynx as a whole.

To study further the development and ultimate appearance of the epithelium of the larynx and to attempt to arrive at some conclusion concerning the significance of the change, 25 embryo larynges were studied, ranging from 25 mm. to term. One each of the following crown-rump length fetuses was fixed in formalin: 25 mm., 30 mm., 65 mm., 95 mm., 125 mm., 150 mm., 180 mm., and 200 mm. Following dissection, these specimens were refixed in Bouin's solution for three days. They were imbedded in nitrocellulose and cut serially at 10 microns*. Every tenth section was then stained with hematoxylin and eosin and mounted. The 25 mm. embryo was cut transversely. The others were cut horizontally, coronally, from anterior to posterior. For relative ages of the various crown-rump lengths given, see the table in Fig. 1.

EMBRYO DEVELOPMENT.

Estimated age in days	C. R. length in mm.
32	5.0
40	13.4
46	17.0
55–60	30.0

Age (in lunar months)	C. R. length in mm.
3	55.
4	100.
5	150.
6	200.
7	230.
8	265.
9	300.
10	335.

Fig. 1. GROWTH AND DEVELOPMENT OF THE EMBRYO. Adapted from Hamilton, Boyd & Mossman.

It must be pointed out that the only accurate measurement of embryo age is a record of coitus and the menstrual history.

* The author is greatly indebted to Mrs. Helen F. Burn for countless hours, days and months spent preparing these many sections, each one so beautifully done.

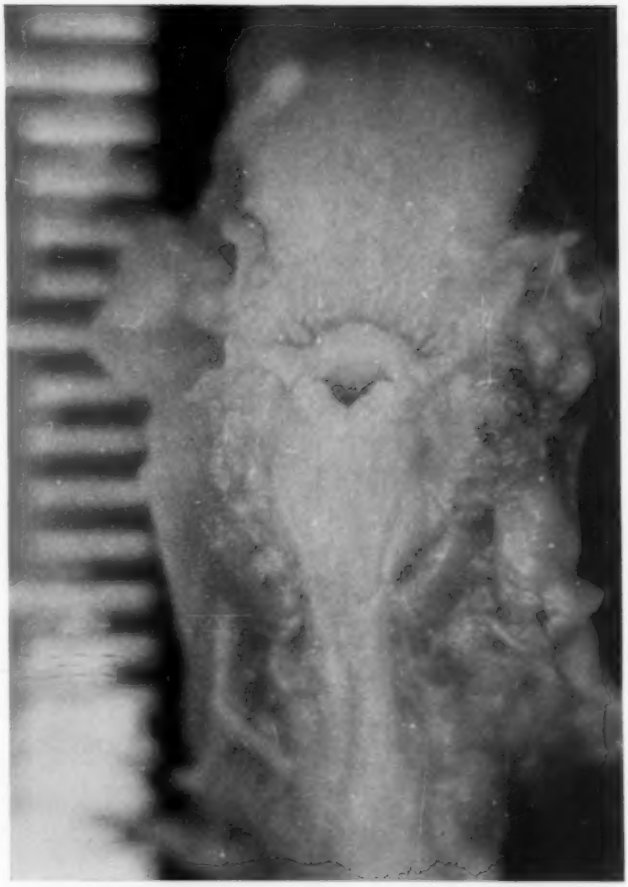

Fig. 2. Photograph of a 75 mm. Embryo Larynx. The esophagus has been excised; the tongue is attached. Scale in millimeters at left.

These factors not being available, the age is estimated by measuring either the crown-rump length, which I have done, or the crown-heel length or the neck-rump length. The crown-rump length (C.R.) is the measurement of the vertex of the skull to the midpoint between the apices of the buttocks.

Fig. 1, adapted from Hamilton, Boyd and Mossman,[11] "Human Embryology," gives C.R. lengths and respective ages. The gross appearance of the 75 mm. and 150 mm. larynges is

Fig. 3. Photograph of a 150 mm. Embryo Larynx; esophagus excised, anterior tip of tongue removed. Scale in millimeters at right.

shown in the photographs, (see Figs. 2, 3, and 4.) The esophagus had been resected in each.

Fig. 5 is a photograph of the interior of the 150 mm. larynx.

The larynx was incised posteriorly and laid open. To provide some comparison between the size and development of the

Fig. 4. Photograph of a 150 mm. Embryo Larynx; esophagus excised to lateral margin. Scale in millimeters at left of picture.

larynx and the size and development of the entire fetus at an almost comparable stage, Figs. 6 and 7 are photographs of a

50 and a 95 mm. embryo, respectively. Two adult larynges were studied, dissected and sectioned.

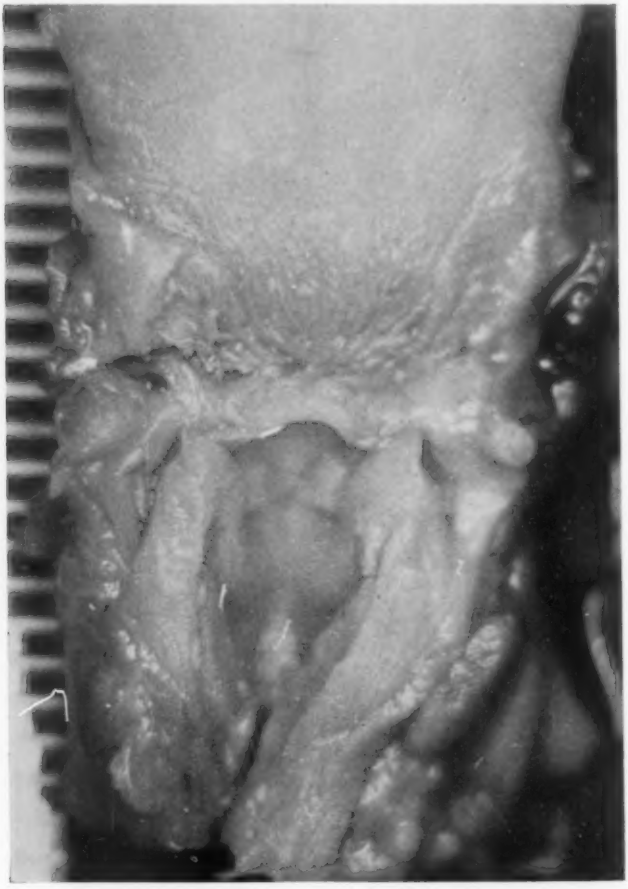

Fig. 5. Photograph of 150 mm. Embryo Larynx Interior; esophagus excised; larynx opened posteriorly. Scale in millimeters at left.

Fig. 8 indicates the approximate area from which the section was taken of which the photomicrograph (see Fig. 9)

was made. The epithelium shown in the photomicrograph in Fig. 9, is taken from the larynx of an 88-year-old female who died of pyelonephritis. This specimen had been fixed in for-

Fig. 6. Photograph of a 52 mm. Embryo. Scale in millimeters at left.

malin and was imbedded in paraffin using the dioxine method. The sections were cut at six microns and also stained with hematoxylin and eosin.

In order to provide continuity of description of the changes

observed in the laryngeal epithelium I would like to begin with the first appearance of the respiratory anlage and proceed through the various stages of embryonic development.

Fig. 7. Photograph of a 95 mm. Embryo. Scale in millimeters at left.

For information concerning the stages prior to the 25 mm. embryo which I have studied, I have translated the work of Soulie and Bardier.[21]

The first appearance of the respiratory apparatus is in the 3 mm. embryo (approximately 21 days) in the form of an evagination which looks like a vertical groove located beside the anterior wall of the cephalic portion of the foregut above the fourth branchial arch. The termination of this area below is a small dilatation, or diverticulum, which is the primitive pulmonary bud. This evagination or mound is called the fur-

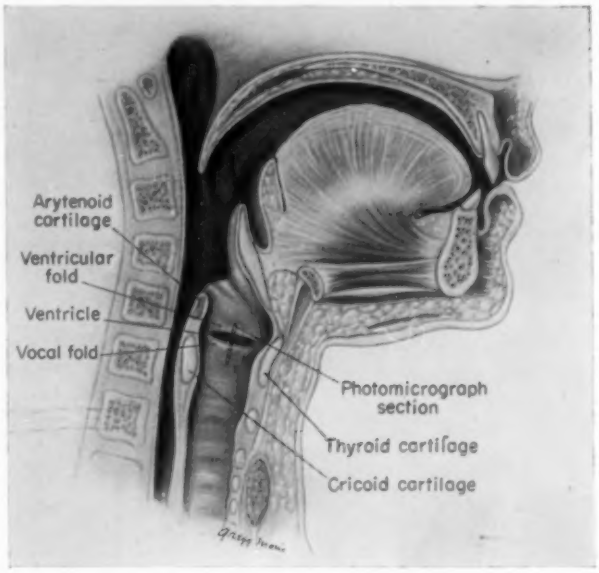

Fig. 8. Adult Larynx indicating area from which photomicrograph made.

cula and is really the primordium of the epiglottis, which is the earliest portion of the larynx to appear; however, the epiglottis does not achieve its definitive form until approximately the fifth month of intrauterine life.

The epithelial walls which cover this above-mentioned groove are visible in the 3, 4, and 5 mm. embryos. They are composed of three rows of cells which are embryonic, stratified polyhedral and rest directly on the underlying mesen-

chyme. In the 6 mm. embryo the first outline of a larynx can be observed. Here the respiratory groove previously described begins to close and communicates with the pharynx through a

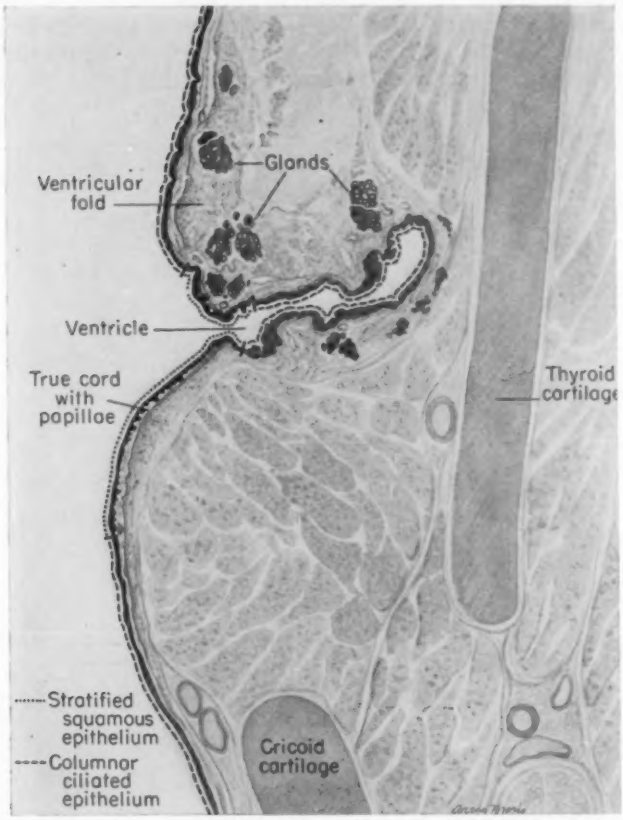

Fig. 9. Drawing made from a photomicrograph of a vertical section of the adult larynx.

narrow elongated opening. Two swellings appear which help to make the closure. These are rudimentary arytenoids. The furcula which is now the epiglottis is joined on each side to the upper extremity of the just described arytenoid swelling

by a small fold which occupies the end of the groove. Each of these folds represents the first outline of the corresponding aryteno-epiglottic fold.

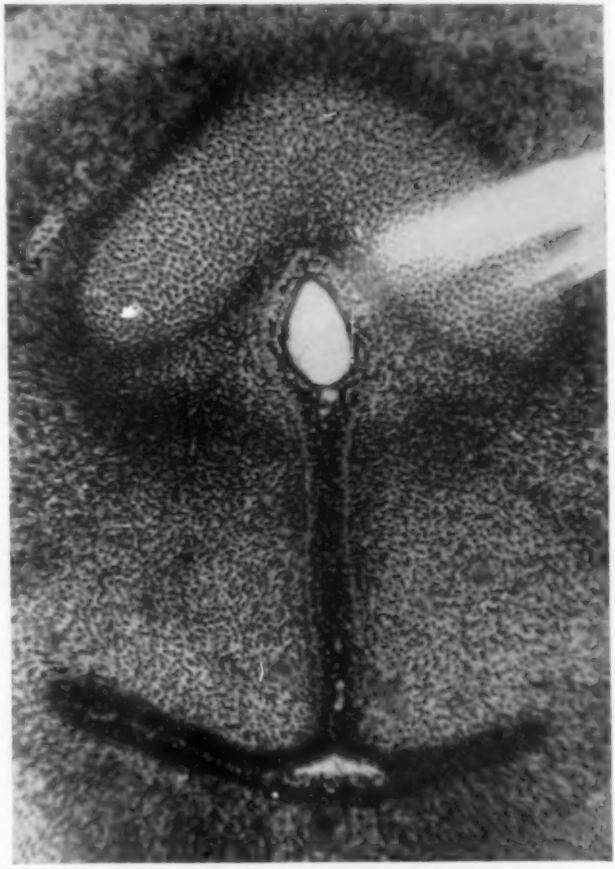

Fig. 10—a. 25 mm. Embryo Larynx.

Thus in the embryo through the 6 and 7 mm. stage, the laryngeal cavity is open throughout its extent. It is par-

tially obliterated in the 8 mm. embryo by the fusion of the little primordial arytenoids and by the fusion of the respective layers of embryonic, polyhedral stratified epithelium

Fig. 10—b. 65 mm. Embryo Larynx.

which I have described as lining each side of the laryngeal cleft. Laryngeal cartilages first begin to appear in the 19 mm. (40 days) embryo. The mucosa of the larynx remains the

same throughout. In the 30 mm. (60 to 70 days) embryo, the number of layers of cells in this embryonic, stratified epithelium increases. The vocal cords begin to differentiate.

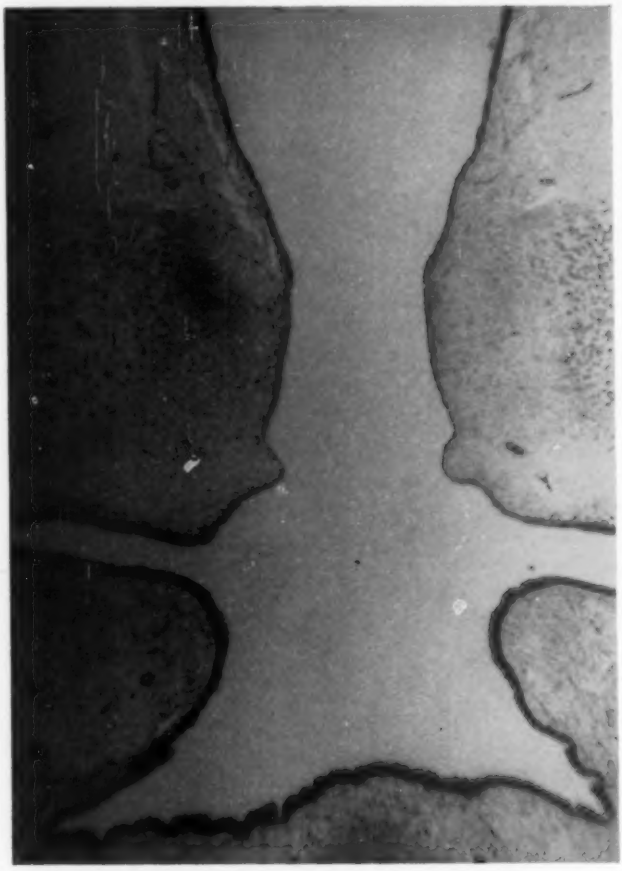

Fig. 10—c. 95 mm. Embryo Larynx.

The glottis really consists of three distinct parts at this stage, an anterior part which lies between the vocal cords and which is covered with a surface epithelium which is be-

ginning to assume a cylindrical form, a middle part which corresponds to the area of the arytenoid cartilages, and a posterior part which is composed of the cavity of the cricoid.

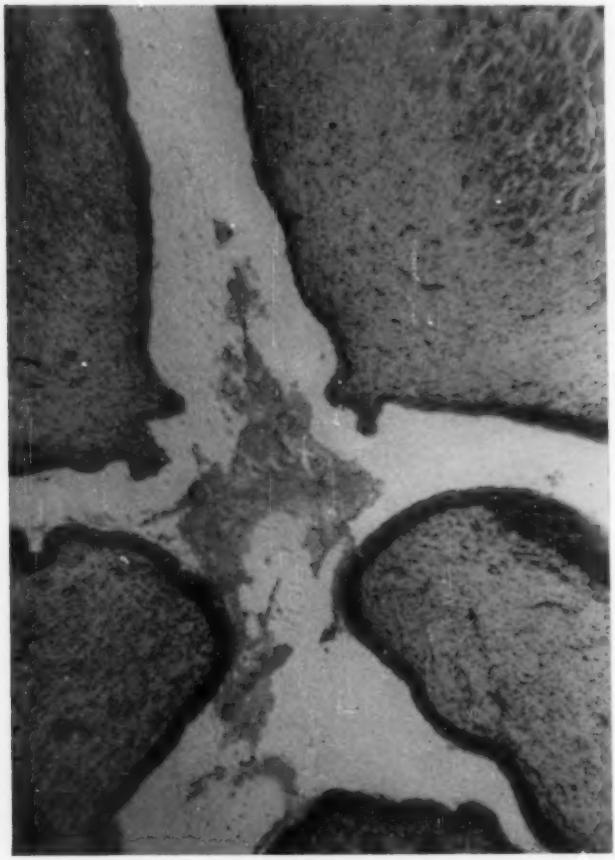

Fig. 10—d. 125 mm. Embryo Larynx.

In the inter-arytenoid space the layers of previously fused epithelium are beginning to separate, and here we still find the embryonic, polyhedral cells.

Ciliated epithelium appears on the epiglottis and at the vestibule of the larynx in the 40 mm. embryo. The glottic surface of the vocal cord is still lined with an epithelial layer of polyhedral cells some five- or six-cell layers thick. Beginning at about the 10th or 11th week the epithelium previously fused, begins to separate as the true vocal cords appear. The larynx assumes in section somewhat the shape of a "T" with the cross bar curved and representing the base of the tongue. One area of the larynx remains fused longer than any other; that is the area which later becomes the incisura inter-arytenoidea. It is fused even into the 95 mm. embryo (approximately 15 weeks).

The formation of the incisura and thus the separation of the epithelium occurs in approximately the 150 mm. embryo (about the fifth lunar month or 20th week). At the 95 mm. fetus stage the vocal cords show a rather cuboidal, somewhat embryonic epithelium, which extends into the opening of the ventricle. In the ventricle itself and above the vocal cords, the epithelium is a beautiful, ciliated variety. See photomicrographs for detail (see Fig. 10).

I should like to emphasize that from a study of the embryos sectioned for this study, and from the description of the embryos sectioned by Soulie and Bardier,[21] Kanthack,[17] Kallius,[16] and others, I find that the differentiation of the epithelium of the larynx is always an orderly process occurring in certain places at certain definite times. The epithelium initially is an embryonic, polyhedral variety. Some of it becomes columnar, ciliated and the rest becomes cuboidal and then stratified squamous. This is well demonstrated in the 95 and 125 mm. fetuses where the epithelium is columnar or prismatic stratified ciliated in all the vestibular areas, and is stratified pavement-like on the true cord and entrance to the ventricle. The changes may be seen in the photomicrographs of both the 95 mm. and 125 mm. embryos.

The transition from one variety of epithelium to the other is rather sharp, particularly on the side of the ventricle. Cilia never develops in the interarytenoid region. The vocal cord itself never develops any ciliated cells. In the 150 mm. and 180 mm. fetuses, (from about the middle of the fifth month)

the stratified squamous epithelium of the vocal cord diminishes in thickness because of the desquamation of the superficial layers.

Fig. 10—e. 200 mm. Embryo Larynx.

From the time (about the middle of the third month) that the ventricles have achieved their definitive form, the false

cords, which probably should be more properly called at this stage of development the ventricular bands, are lined with cylindrical, often stratified ciliated epithelium. In a five-month female, described by Soulie and Bardier, this area of ciliated epithelium was still visible, whereas in a male infant of six months it had been replaced by stratified squamous epithelium.

SUMMARY.

The earliest epithelium of the larynx is embryonic, polyhedral, which fuses and, at about the time of the beginning of the development of the true cords, separates. The embryonic epithelium of the true cords becomes cuboidal and then stratified squamous. This includes the area extending into the ventricle. The remainder of the larynx, with the exception of the continuation of the vocal cord into the inter-arytenoid area, becomes lined with ciliated epithelium which is columnar and pseudo-stratified.

During the first year of life, with the further development of the larynx itself and with the anatomical changes in the relationships of the true cords, ventricles and ventricular folds, the area of the ventricular folds becomes covered with a squamous epithelium comparable to that of the true cord.

The problem of obtaining a good microscopic section of an adult larynx is a considerable one, because of its location in the interior of the human body and because of the difficulty fixing this particular tissue rapidly enough. Few really good microscopic sections of adult laryngeal epithelium are in existence. From a study of those available, and of the larynges which we sectioned (see Fig. 9 drawing made from photomicrograph of the adult larynx), I believe that it can be seen that the true cord itself is covered with stratified squamous epithelium, which has small papillae.

The ventricle is lined with ciliated epithelium, which varies in thickness. The false cords are lined with squamous epithelium. The inter-arytenoid area is lined with squamous epithelium. There may also be occasional islands of squamous epithelium in the adult larynx, but I believe these are rare. In general, I think they result from pathological changes. I like to think of the development of the epithelium which I

have here outlined as being a "physiological metaplasia," as Kanthack describes it. As a matter of speculation, if further progression in the metaplasia of the epithelium of the larynx is pathological, as has been demonstrated and described above in cases of syphilis and tuberculosis, it is conceivable that a continuation of this progression could result in the production of malignant change. Then if one could determine what causes some individuals to continue the progressive metaplasia of their laryngeal epithelium and thus develop carcinoma, new light might be shed on this problem. Recent studies have suggested the possibility of a relationship between carcinoma of the breast and endocrine inhibitor substances. It is not inconceivable that in the normal individual some such mechanism controls the metaplasia of the epithelium of his larynx.

CONCLUSION.

From a review of the literature and a personal study of 25 embryos and two adult larynges with serial sections of eight of the embryos and both of the adults, it has been demonstrated that the epithelium of the larynx differentiates in a definite pattern throughout embryonic life to achieve its adult appearance. This is physiological metaplasia. Absence or deficiency of an inhibitor substance which prevents metaplasia from progressing beyond this physiological stage in normal individuals, could be a factor in the development of laryngeal carcinoma. This merits further investigation.

REFERENCES.

1. Bailey's Textbook of Histology, p. 505. The Williams & Wilkins Co., Baltimore, 1948.

2. Bremer, J. L.: A Textbook of Histology, 5th Ed., p. 325. Blakiston, New York, 1936.

3. Cowdry, E. V.: A Textbook of Histology, p. 299. Lea & Febiger, Philadelphia, 1934.

4. Cowdry, E. V.: A Textbook of Histology, 3rd Ed., p. 208. Lea & Febiger, Philadelphia, 1944.

5. *a.* Dolkowski, E. V.; *b.* Frankenhauser, C.; *c.* Henle, J.; *d.* Kolliker, A.; *e.* Luschka, H. V., cited by Heymann, P.: Die Histologie der Schleimhaut des Kehlkopfes und der Luftrohre. *Handbuch d. Laryngol. u. Rhinol.*, 1, 1:134-164, Wein, 1898.

6. Frankel, B.: Studien zur feineren Anatomie des Kehlkopfes. *Arch. f. Laryngol. u. Rhinol.*, 1, 1:250-257, Berlin, 1898.

7. Galen, cited by Wright, Jonathan: The Nose and Throat in Medical History. *Privately Published*, p. 120.

8. GANGHOFNER, F., cited by KALLIUS, E.: Beitrage zur Entwickelungsgeschichte des Kehlkopfes Anat., 9:303-363, *Heft*, Wiesbaden, 1897.

9. GREEP, ROY O.: *Histology*, p. 519. Blakiston, New York, 1954.

10. HAM, ARTHUR W.: *Histology*, p. 475, Lippincott, Philadelphia, 1950.

11. HAMILTON, W. J.; BOYD, J. D., and MOSSMAN, H. W.: Human Embryology, 2nd Ed., p. 106. The Williams & Wilkins Co., Baltimore, 1952.

12. HENLE, JACOB, cited by STEVENSON, R. S., and GUTHRIE, D. A.: A History of Otolaryngology, p. 80. The Williams & Wilkins Co., Baltimore, 1949.

13. HEYMANN, P.: Die Histologie der Schleimhaut des Kehlkopfes und der Luftrohre. *Handbuch d. Laryngol. u. Rhinol.*, 1, 1:134-164, Wein, 1898.

14. HEYMANN, R.: Beitrage z. Kenntniss d. Epithels u. d. Drusen d. Menschliches Kehlkopfes im. ges. u. krank. Zustande. *Virchow's Arch.*, 118:320-348, 1889.

15. JORDAN, H. E.: A Textbook of Histology, 8th Ed., p. 291. Appleton, New York, 1947.

16. KALLIUS, E.: Beitrage zur Entwickelungsgeschichte des Kehlkopfes, Anat., 9:303-363, Hefte, Wiesbaden, 1897.

17. KANTHACK, A. A.: Studien uber die Histologie der Larynxschleimhaut. *Arch. f. Pathol. Anat.*, 118:137-147, 273-294, 326-342, Berlin, 1889.

18. MAXIMOW, A. A., and BLOOM, WM.: A Textbook of Histology, 5th Ed., p. 457. Saunders, Philadelphia, 1948.

19. SEMON, SIR F.: Remarks on a Case of Congenital Web Between the Vocal Cords. *Brit. Med. Jour.*, 1, 1373-1375, London, 1898.

20. SHARPER-SCHAFER, SIR E.: Essentials of Histology, 13th Ed., p. 317, Lea & Febiger, Philadelphia, 1934.

21. SOULIE, A., and BARDIER, E.: *a.* Sur les Premier stades du Developpement du Larynx Chez le Foetus Humain. *Compt. Rend de l'Ass. de Anat.*, 8:41-46, Paris, 1906. *b.* Recherches sur le Developpement du Larynx Chez l'Homme. *Jour. de l'Anat. et Phyiol.*, 43:137-240, Paris, 1907.

22. STOHR, PHILIPP: Lehrbuch der Histologie, 23rd Ed., p. 35, 36, 333, Gustav Fischer, Jena, 1933.

23. TOURNEUX, M. F.: Sur le Developpement de l'Epithelium et des Glands du Larynx et de la Trachee Chez l'Homme. *Compte. Rend. de la Soc. de Biolog.*, 2, 8:250, Paris, 1885.

24. VIDONI, G.: Sullo Sviluppo E Sull'istogenesi del Labbro Vocale. *Arch. Ital. di Otologia.*, 64(3):297-317, 1953.

2000 Van Ness Ave.

STRESS AND DISEASE.*

HANS SELYE, M.D.,

Montreal, Canada.

It is impossible to touch upon all aspects of this topic in a single lecture. The literature on stress and the adaptive hormones, which was first analyzed in the form of an extensive monograph in 1950,[1] is now growing at the rate of four to six thousand publications per annum. A survey of these, will be found in our "Annual Reports on Stress,"[2,3,4,5] which are designed to aid the dissemination of information and the coordination of new facts in this domain.

The subject has recently been summarized in the form of seven informal illustrated lectures, which attempt to explain the theoretical background of this topic, as far as its understanding is essential for the comprehension and logical treatment of certain diseases which we consider to be primarily "diseases of adaptation."[6]

It may be opportune to take stock now after 20 years of stress-research, and present here the most fundamental facts which we have learned about the physiopathology of stress; however, for those not particularly familiar with the subject, it may be well first to give a glossary of the most common technical terms used in this field.

GLOSSARY OF TECHNICAL TERMS AND ABREVIATIONS.

Stress—Non-specific deviation from the normal resting state; it is caused by function or damage and stimulates repair.

Non-specific change—Change which can be produced by many or all agents.

Specific change—Change which can be produced only by one or few agents.

G-C—Glucocorticoid (*e.g.*, cortisone, cortisol).

M-C—Mineralocorticoid (*e.g.*, desoxycorticosterone, aldosterone).

---

* Based on a lecture given before the American Laryngological, Rhinological and Otological Society, Inc., Hollywood, Florida, March 15, 1955, and on a chapter of the "Fourth Annual Report on Stress—1954," by H. Selye and G. Heuser (Acta Inc., Med. Publ., Montreal).

Editor's Note: This ms. received in Laryngoscope Office and accepted for publication, May 2, 1955.

A-C—Antiphlogistic corticoid (*e.g.*, cortisone, cortisol). Essentially synonymous with G-C, since the antiphlogistic glucocorticoid, lympholytic and catabolic activity tends to run parallel in the steroids so far examined.

P-C—Prophlogistic corticoid (*e.g.*, desoxycorticosterone, desoxocortisone). Essentially synonymous with M-C, since the prophlogistic activity tends to run parallel with mineralocorticoid activity in the compounds so far examined.

DCA—Desoxycorticosterone acetate or DOCA.

Cortisol—Hydrocortisone, Kendall's compound "F."

STH—Somatotrophic hormone, or growth hormone of the hypophysis.

MAD—17-methylΔ^5-androsterone-3β, 17β-diol. (Ordinary methylandrostenediol).

Precursors of the Stress Concept. Ever since man used the word "disease" he had some, at least subconscious, inkling of the stress concept. The very fact that a single term can be used to denote a great variety of individual maladies, clearly indicates that they have something in common. They possess, as we would now say, some non-specific features which permit us to distinguish disease from the condition of health; yet, precisely because these manifestations are not characteristic of any one disease, they have received little attention in comparison, with the specific ones. They were thought to be of lesser interest for, unlike the latter, they did not help to recognize the "eliciting pathogen" or lend themselves to any effective type of specific therapy.

Several early investigators nevertheless have attempted to elucidate the mechanisms involved in such non-specific reactions. Since our knowledge of the nervous system antedates, by far. the development of modern endocrinology, it is understandable that, among the two great integrating systems of the body, the nervous and the hormonal systems, the former was the first to be examined from this point of view. Ricker, Sparansky, Reilly, Hoff and many others have gathered important data concerning the rôle of the nervous system in such non-specific reactions as fever, polymorphonuclear leucocytosis, inflammation, etc.

In the domain of what may be called "physiologic stress," W. Cannon's studies helped us to understand the part played by the sympathetic nervous system and its humoral effector substances; furthermore, quite independently, a great deal of

progress has been made in the study of pituitary and adrenocortical hormones by chemists, physiologists and clinicians, too numerous to mention by name.

All the knowledge acquired as a result of these early investigations was indispensable for the eventual formulation of the stress-concept, whose leading motive is one of unification. Additional experiments had to be performed, however, to show that the many non-specific responses of individual target organs are closely integrated and actually represent part of a single biological response—the general adaptation syndrome. These investigations, which will be outlined below, made it evident that the "stress pattern" of reaction plays an integral part in the most varied physiologic, pathologic and pharmacologic phenomena.

The Concept of Stress. By a series of experiments on animals, it was demonstrated in 1936 that the organism responds in a *stereotypical* manner to a variety of widely different factors, such as: infections, intoxications, trauma, nervous strain, heat, cold, muscular fatigue or x-irradiation. The specific actions of all these agents are quite different. Their only common feature is that they place the body in a state of general (systemic) stress. We concluded, therefore, that the stereotypical response, which is superimposed upon all specific effects, represents the somatic manifestations of non-specific "stress" itself.

What is Non-specific "Stress?" The term had long been used in physics to denote the interaction between a force and the resistance opposed to it; for instance, pressure and tension can put inanimate matter under stress. The above mentioned non-specific response was thought to represent the biologic equivalent of such physical stress. The term has now been quite generally accepted in this sense, not only in English but, since attempts to translate "stress" led to much confusion, also in most other languages.

The Concept of the G-A-S. The most outstanding manifestations of this stress-response were: *adrenocortical enlargement* with histologic signs of hyperactivity; *thymicolymphatic involution* with certain concomitant changes in the blood-count (eosinopenia, lymphopenia, polynucleosis) and *gastro-intes-*

tinal ulcers, often accompanied by other manifestations of *damage or "shock."*

We were struck by the fact that, while during this reaction all the organs of the body show involutional or degenerative changes, the adrenal cortex actually seems to flourish on stress. We suspected this adrenal response to play a useful part in the systemic, non-specific adaptive reaction, which we visualized as a "call to arms" of the body's defense forces and named the "alarm reaction."[7]

Subsequent studies showed that the alarm reaction is but the first stage of a much more prolonged *General Adaptation Syndrome (G-A-S)*. The latter comprises three distinct stages, namely:

1. *The Alarm Reaction* (A-R), in which adaptation has not yet been acquired.

2. *The Stage of Resistance* (S-R), in which adaptation is optimal.

3. *The Stage of Exhaustion* (S-E), in which the acquired adaptation is lost again.

The Mechanism of the G-A-S. In order to elucidate the kinetics of this syndrome we proceeded as follows:

Rats were adrenalectomized and then exposed to stressor agents. This showed us that in the absence of the adrenals, stress can no longer cause thymico-lymphatic involution or characteristic blood-count changes.[8]

When adrenalectomized rats were treated with the impure cortical extracts available at that time, it became evident that thymico-lymphatic involution and the typical blood-count changes could be produced by adrenal hormones, even in the absence of the adrenals; therefore, these changes were considered to be indirect results of stress mediated by corticoids.[8,9]

Conversely, the gastro-intestinal ulcers and other manifestations of pure damage or shock were actually more severe in adrenalectomized than in intact animals and could be lessened by treatment with cortical extracts. It was concluded that these lesions are not mediated through the adrenal; in fact,

they are actually combated by an adequate adreno-cortical response to stressor agents.[8]

What Stimulates Adreno-cortical Function During Stress? In the course of the next year, we found that among many surgical interventions tried, only hypophysectomy prevents adrenal response during the alarm reaction; hence, we concluded that stress stimulates the cortex through an adreno-corticotrophic hormone, now known as ACTH.[10,11]

Then pure cortical steroids became available, thanks first of all to the classical investigations of Kendall and Reichstein. With these, we could show that administration of *mineralo-corticoids* or *M-Cs* (such as desoxycorticosterone) produces experimental replicas of the so-called *hypertensive and inflammatory "rheumatic" diseases; notably, nephrosclerosis, hypertension, vascular lesions* (especially periarteritis nodosa and hyalin necrosis of arterioles),[12] as well as arthritic changes resembling, in acute experiments, those of rheumatic fever and, after chronic treatment, those of rheumatoid arthritis;[13] yet, even very high doses of mineralo-corticoids did not induce any noteworthy thymico-lymphatic or blood-count changes, such as were caused by cortical extracts.

Significantly, exposure of animals to certain non-specific stressor agents (*e.g.*, cold) produced marked adreno-cortical enlargement and organ changes very similar to those elicited by the administration of mineralo-corticoids.[14] Many investigators doubted that secretion of *M-Cs* could be involved in the pathogenesis of disease, since the very existence of natural, endogenous *M-Cs* was questioned. Indeed, until quite recently, some of the most eminent students of the adrenal advocated the "unitarian theory," which held that the gland secretes only one corticoid, so that a derangement in the balance between antagonistic cortical hormones would be impossible. This concept was definitely disproven by the isolation of *aldosterone* from both the tissue and the venous blood of the adrenals.[15]

Extracts rich in *gluco-corticoids or G-Cs*, such as cortisol and cortisone on the other hand, were highly potent in causing *thymico-lymphatic* involution and in eliciting the characteristic blood-count changes of the alarm reaction. They also

tended to inhibit the inflammatory "rheumatic-like" changes which can be elicited in animals by mineralo-corticoids. Thus, in many respects, the two types of corticoid hormones antagonize each other.[1,9]

Another interesting activity of the corticoids, discovered at about this time, is their singular effect upon the *central nervous system* of animals. A variety of steroids, among which figured both G-Cs (*e.g.*, cortisone) and M-Cs (*e.g.*, DCA), as well as other steroid hormones, and hormone-metabolites (*e.g.*, pregnanediol, pregnanedione), proved to possess the property of causing a state of great excitation and confusion, followed by marked depression of all reflex activities and eventually deep anesthesia.[16]

This observation raised the question whether a pronounced increase in the activity of endogenous corticoids could be responsible for certain nervous emotional accompaniments of exposure to stress. After the introduction of cortisone into clinical therapy, it became evident that in man this hormone can also exert a powerful effect upon the central nervous system. In animals, both G-Cs and M-Cs exhibit this effect; hence we shall have to watch for it as soon as patients will be treated with large doses of aldosterone.

The terms "gluco-corticoids" and "mineralo-corticoids" emphasize the salient metabolic actions of these substances; from a clinical point of view, however, their effects upon inflammation are perhaps of even greater interest. Since the gluco-corticoids inhibit inflammation, while the mineralo-corticoids enhance it, the G-Cs may appropriately be called *"antiphlogistic corticoids"* or *"A-Cs,"* and the M-Cs *"prophlogistic corticoids,"* or *"P-Cs"* when they are discussed with reference to their effects upon inflammation. It remains to be seen, however, whether G-C and A-C (or M-C and P-C) activities necessarily run parallel in all steroid compounds, including those (like aldosterone) which have not yet been fully examined for these effects.

Inflammatory granulomas, especially those produced in the vicinity of joints by the local applications of irritants (*e.g.*, formalin, mustard powder), as well as certain allergic reactions, are likewise aggravated by P-Cs and inhibted by A-Cs. Apparently, the response of the adrenal cortex is most important not only in defense against systemic stress (affecting the whole organism), but also in the manifold topical defense reactions which occur upon exposure to *local stress* (*e.g.*, bacterial or chemical irritants, response of a "shock organ" to an allergen).[1,14]

These findings helped to formulate the concept of the Local

Adaptation Syndrome (L-A-S) to be discussed below (see pages 508-509).

In this connection, the hormone sensitivity of certain so-called *"anaphylactoid inflammatory reactions"* is of special interest. Actually, our attention had first been called to a possible relationship between the adrenal cortex and inflammation by an incidental observation on rats, given parenteral injections of egg-white. It was found that the rat is naturally hypersensitive to egg-white and responds to the intraperitoneal or intravenous administration of this substance by an acute serous inflammation of the paws and snout. This inflammatory response was greatly aggravated in adrenalectomized animals (presumably because they could not defend themselves by the endogenous production of A-Cs).

On the other hand, it was prevented by treatment with systemic stressors, directly in proportion to the adreno-cortical enlargement they produced (presumably, as a result of excess A-C secretion).[11] Subsequently, it could be shown that cortisone and ACTH inhibit, while certain crude anterior-pituitary preparations and desoxycorticosterone aggravate this anaphylactoid type of acute inflammation.[18] ,

Curiously, our crude *anterior pituitary extracts* also duplicated most of the above mentioned actions of P-Cs upon the *cardiovascular system, the blood-pressure, the connective tissue (inflammation) and the kidneys.*[9,19]

The hypophyseal preparations which we used were definitely corticotrophic, in that they enlarged the adrenal cortex, but they were particularly rich in the so-called "growth hormone" or *somatotrophic hormone (STH)*. This made it difficult to interpret our early experiments, in which such crude extracts were used, because we were unable to distinguish clearly between the effects of ACTH and STH; however, as soon as we obtained purified ACTH, it became evident that the above mentioned pathogenic actions of the crude anterior-pituitary preparations could not be due to their ACTH content, since even the highest tolerable doses of the pure corticotrophic hormone failed to duplicate their predominant P-C effects.

On the other hand, overdosage with purified STH caused cardiovascular and renal lesions, virtually identical with those previously observed in animals treated with P-Cs. It was then concluded that, probably, the characteristic actions of our crude anterior-pituitary preparations were mainly due to their STH content. It remains to be seen to what extent STH acts indirectly by sensitizing the peripheral tissues to P-Cs. Preliminary observations suggest that the last-mentioned mechanism is more important, although both may be implicated.[20] This point is not yet settled.

From the internist's point of view, perhaps the most interesting rôle of STH in the adaptation syndrome is that it can effectively *combat catabolism and susceptibility to infections.* Animals heavily overdosed with ACTH or A-Cs, tend to lose a great deal of weight. Eventually they die, almost always as a result of generalized septicemia, caused by normally saprophytic micro-organisms. In rats, the lung tissue appears to be singularly predisposed to such infections. Under these conditions, adequate doses of STH prevent the loss of body-weight as well as the excessive microbial proliferation.[21]

It remains to be seen to what extent these actions of STH will prove to be of value in the management of infections in man. but experiments on rats have already demonstrated the great influence of adaptive hormones upon resistance to the human type of tuberculosis. Normally the rat is virtually resistant to tuberculosis bacilli. It may be rendered sensitive by ACTH or A-Cs and this sensitivity can, in turn, be abolished by STH.[22,23]

Conditioning of Hormone Actions. As work along these lines progressed it became increasingly more obvious that the activity of the hormones produced during stress depends largely upon a variety of "conditioning factors." Both the production of the "adaptive hormones" and their effect upon individual target organs proved to be greatly influenced by heredity, age, previous exposure to stress, the nutritional state, etc. Thus, for instance, the production of corticotrophic hormone by the pituitary is enhanced by a high-protein diet, while the action of M-Cs upon most target organs augmented by excess sodium.[5]

Stress itself is perhaps the most effective and most common factor capable of conditioning the actions of adaptive hormones. Thus systemic stress augments the antiphlogistic, lympholitic, catabolic and hyperglycemic actions of A-Cs, while the salient effect of the adaptive hormones, that of modifying the course of inflammation, naturally cannot manifest itself unless some topical stressor first elicited a phlogistic response.

Ingle[24] introduced the concept of the "permissive actions" of corticoids. This term implies that the adrenal hormone does not effect a target of stress itself, although it permits a stressor to act upon it; furthermore,

allegedly the presence or absence of a permissive factor can only allow or disallow a reaction, but is unable to vary its intensity.

To illustrate this concept, one might compare the production of light by an electric lamp to the biologic reaction and the switch to the "permissive factor." The switch cannot produce light, nor regulate the degree of its intensity, but unless it is turned on the lamp will not function.

Correspondingly, the functional signs, generally considered to be characteristics of corticoid-overproduction during stress, would not result from any actual increase in corticoid-secretion, but from the extra-adrenal actions of the stressors themselves. The presence of corticoids would be necessary only in a "supporting capacity" to maintain the vitality and reactivity of tissues.

Actually, it is precisely in the specific and not in the non-specific stress-reactions that the corticoids play a purely "permissive rôle" of this type. Here they are necessary only to prevent stress and collapse, thus keeping the tissues responsive. For instance adrenalectomized rats will not respond to injected STH with somatic growth, or to sexual stimulation with mating, without a minimal maintenance corticoid treatment.

These reactions are in fact not characteristic of the corticoids and could not be duplicated, in the absence of the specific stimulus, even with the highest doses of corticoids. The characteristic functional signs of A-C-overproduction which we see in the alarm reaction (*e.g.*, atrophy of the lymphatic organs, catabolism, inhibition of inflammation) are also impeded by adrenalectomy and restored even by mere maintenance doses of A-Cs in the presence of stress, which sensitizes or "conditions" the tissues to them; however, unlike specific actions, these non-specific effects can also be duplicated in the absence of any stressor if large doses of A-Cs are given, (see "Fourth Annual Report on Stress," pp. 78-85).

The importance of such conditioning influences is particularly striking in the regulation of stress-reactions, because in the final analysis they are the factors which can actually determine whether exposure to a stressor will be met by a physiologic adaptation syndrome, or cause "diseases of adaptation"; furthermore, in the latter instance, these conditioning factors can even determine the selective breakdown of one or the other organ. We are led to believe that differences in predisposition, due to such factors, might explain why the same kind of stressor can cause diverse types of "diseases of adaptation" in different individuals.

Incidentally, it was only on the basis of such experiments that the mechanism through which stress effects the adrenal cortex, could be clarified. We noted that stressors such as "formaldehyde' which caused marked adrenal hypertrophy in the normal but not in the hypophysectomized animal, remained without effect (upon the adrenal), even if the adrenal cortex was prevented from undergoing atrophy by the administration of pituitary extract. The effect of such a drug on the adrenal appears to be an indirect one due to pituitary stimulation."[28]

The Concept of the L-A-S. It had long been known that many local responses to injury are non-specific; it had been noted, for instance, that a variety of "topical stressors" (burns, microbes, drugs) share the power of producing non-specific tissue damage and/or inflammation; however, it is only recently that the close relationship between the systemic and local types of non-specific reactions has been more clearly established.

While the characteristic response of the body to systemic stress is the G-A-S, characterized by manifold morphologic and functional changes throughout the organism, topical stress elicits a "Local Adaptation Syndrome" (L-A-S), whose principal repercussions are confined to the imme-

diate vicinity of the eliciting injury. They consist, on the one hand, of degeneration, atrophy and necrosis; on the other of inflammation, hypertrophy, hyperplasia, and under certain conditions neoplasia.

L-A-S and G-A-S. At first sight, there appears to be no striking similarity between the systemic and the local reaction-type. A patient in traumatic shock furnishes a characteristic example of the G-A-S and, in particular, of its earliest stage, the "shock phase" of the general alarm reaction. An abscess, formed around a splinter of wood represents a typical example of the L-A-S and, in particular, of its "stage of resistance," during which the defensive inflammatory phenomena predominate. On the surface, these two instances of disease reveal no striking similarities, and yet more careful study shows them to be closely related.

The experimental observations which led us to these conclusions have been described elsewhere.[23,28] Let us restate here, however, that among other things, the G-A-S and the L-A-S are thought to be interrelated because:

1. Both are non-specific reactions, comprising damage and defense.

2. Both are triphasic, with typical signs of "crossed resistance" (or, depending upon the stressors used, "crossed sensitization"), during the second stage.

3. Both are singularly sensitive to the so-called "adaptive hormones" (ACTH, STH, corticoids).

4. If the two reactions develop simultaneously in the same individual, they greatly influence one another; that is, systemic stress markedly alters tissue-reactivity to local stress and *vice-versa.*

The Concept of the Diseases of Adaptation. Thus we arrived at the conclusion that the pathogenicity of many systemic and local stressor agents depends largely upon the function of the hypophysis-adreno-cortical system. The latter may either enhance or inhibit the body's defense reactions against stressors. We think that derailments of this adaptive mechanism are the principal factors in the production of certain maladies which we consider, therefore, to be essentially *Diseases of Adaptation.*

It must be kept in mind that such diseases of adaptation do not necessarily become manifest during exposure to stress. This is clearly demonstrated by the observation that temporary overdosage with desoxycorticosterone can initiate a self-sustaining hypertension, which eventually leads to death,

long after hormone administration has been discontinued. Here, we speak of "metacorticoid" lesions. The possibility that a temporary excess of endogenous aldosterone could induce similar delayed maladies deserves serious consideration.

Among the derailments of the G-A-S which may cause disease, the following are particularly important:

1. An *absolute excess or deficiency* in the amount of adaptive hormones (*e.g.*, corticoids, ACTH, STH) produced during stress.

2. An absolute excess or deficiency in the amount of adaptive hormones *retained (or "fixed")* by their peripheral target organs during stress.

3. A disproportion in the relative secretion (or fixation) during stress, of various antagonistic adaptive hormones (*e.g.*, of ACTH and A-Cs, on the one hand, and of STH and P-Cs, on the other).

4. Production by stress of metabolic derangements, which abnormally alter the *target organ's response* to adaptive hormones (through the phenomenon of "conditioning").

5. Finally, we must not forget that although the hypophysis-adrenal mechanism plays a prominent rôle in the G-A-S, *other organs* which participate in the latter (*e.g.*, nervous system, liver, kidney) may also respond abnormally and become the cause of disease during adaptation to stress.

Summary of Observations. To summarize, we might say that all agents which act upon the body or any of its parts exert dual effects:

1. Specific actions, with which we are not concerned in this review, except insofar as they modify the non-specific actions of the same agents.

2. Non-specific or stressor effects, whose principal pathways (as far as we know them today) are illustrated in Fig. 1.

The stressor acts upon the target (the body or some part of it) directly (thick arrow) and indirectly through the pituitary and adrenal.

Through some *unknown pathway* (labelled by a question mark), the "first mediator" travels from the directly injured target area to the *anterior pituitary*. It notifies the latter that a condition of stress exists and thus induces it to discharge ACTH.

It is quite possible that this "first mediator" of hormonal defense is not always the same. In some instances it may be an adrenaline discharge, in others a liberation of histamine-like toxic tissue metabolites, a nervous impulse or even a sudden deficiency in some vitally important body constituent (such as glucose or an enzyme).

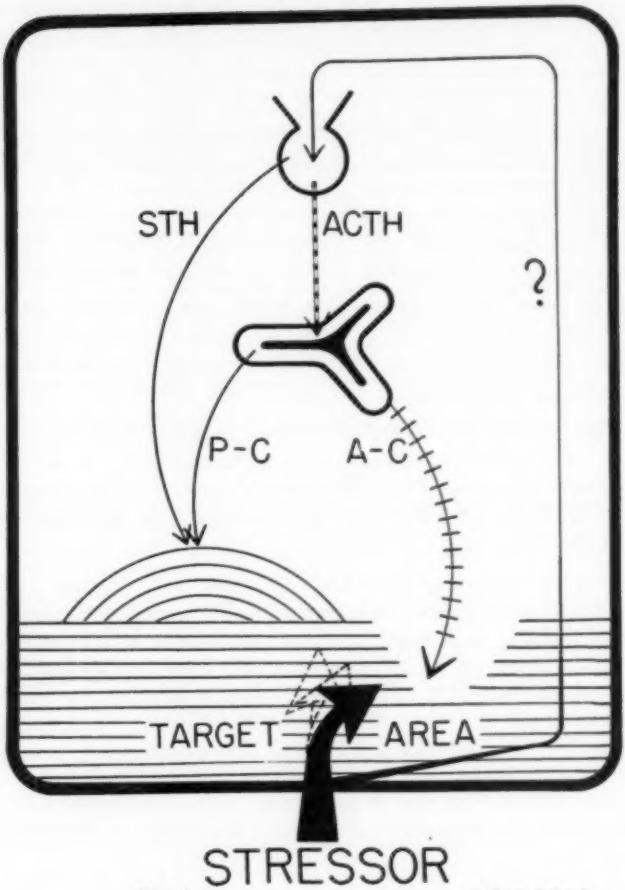

Fig. 1. (after Selye[6])

ACTH stimulates the *adrenal cortex* to discharge corticoids. Some of these, the *prophlogistic corticoids* (P-C), stimulate the proliferative ability and reactivity of connective tissue; they enhance the "inflammatory potential." Thus, they help to put up a strong barricade of connective tissue through which the body is protected against further invasion by the pathogenic stressor agent.

Under ordinary conditions, however, ACTH stimulates the adrenal much more effectively to secrete *antiphlogistic corticoids* (A-C). These inhibit the ability of the body to put up granulomatous barricades in the path of the invader; in fact, they tend to cause involution of connective

tissue with a pronounced depression of the inflammatory potential and thus they open the way to the spreading of infection.

It is not yet known whether ACTH always stimulates the adrenal to produce the various corticoids in the same proportion and always with a great predominance of A-Cs. Certain recent experiments[27] suggest that, depending upon conditions, ACTH may cause the predominant secretion of one or the other of the steroid hormones. Be this as it may, the *somatotrophic hormone* (STH) of the pituitary increases the inflammatory potential of connective tissue, very much as the P-Cs do; hence, it can sensitize the target area to the actions of the latter.

It is possible that the hypophysis also secretes some special corticotrophin which induces the adrenal to elaborate predominantly PC-s; indeed, STH itself may possess such effects, but this has not yet been proven. In any event, even if ACTH were the only corticotrophin, the actions of the corticoids produced under its influence can be vastly different, depending upon "conditioning factors" (such as STH), which specifically sensitize the target area for one or the other type of corticoid action. Actually, conditioning factors could even alter the response to ACTH of the adrenal cortex itself, so that its cells would produce more A-Cs or P-Cs. Thus, during stress, one or the other type of effect can predominate.

The fundamental reaction-pattern to topical stressors is a local adaptation syndrome with inflammation, to systemic stressors, the general adaptation syndrome. Various modifications of these two basic responses constitute the essence of most diseases.

Outlook Suggested by These Observations. Pasteur, Koch and their contemporaries introduced the concept of specificity into medicine, a concept which proved to be of the greatest heuristic value up to the present time. Each individual, well-defined disease, they held, has its own specific cause. It has been claimed by many that Pasteur failed to recognize the importance of the "terrain," being too preoccupied with the pathogen (micro-organism) itself. His work on induced immunity shows that this is incorrect. Indeed, allegedly, at the end of his life he said: *"le microbe n'est rien, le terrain est tout."*

The theory which directed the most fruitful investigations of Pasteur and his followers was that the organism can develop specific adaptive reactions against individual pathogens, and that by imitating and complementing these, whenever they are short of optimal, we can treat many of the diseases which are due to specific pathogens.

To our mind, the G-A-S represents, in a sense, the negative counterpart, or mirror image, of this concept. It holds that

many diseases have no single cause, no specific pathogen, but are largely due to non-specific stress, and to pathogenic situations which result from inappropriate responses to such non-specific stress.

Our blueprint of the pathways through which stress acts may be partly incorrect; it is certainly quite incomplete; but in it we have a basis for the objective scientific dissection of such time-honored, but hitherto rather vague, concepts as the rôle of "reactivity," "constitution and resistance" or "non-specific therapy," in the genesis and treatment of disease.

If we may venture a prediction, we would like to reiterate our opinion *that research on stress will be most fruitful if it is guided by the theory that we must learn to imitate—and if necessary to correct and complement—the body's own auto-pharmacologic efforts to combat the stress-factor in disease.*

REFERENCES.

1. SELYE, H.: Stress. The Physiology and Pathology of Exposure to Stress. *Acta, Inc.*, Med. Publ., Montreal, 1950.

2. SELYE, H.: First Annual Report on Stress. *Acta, Inc.*, Med. Publ., Montreal, 1951.

3. SELYE, H., and HORAVA, A.: Second Annual Report on Stress. *Acta, Inc.*, Med. Publ., Montreal, 1952.

4. SELYE, H., and HORAVA, A.: Third Annual Report on Stress. *Acta, Inc.*, Med. Publ., Montreal, 1953.

5. SELYE, H., and HEUSER,. G.: Fourth Annual Report on Stress. *Acta, Inc.*, Med. Publ., Montreal, 1954.

6. SELYE, H.: The Story of the Adaptation Syndrome. *Acta, Inc.*, Med. Publ., Montreal, 1952.

7. SELYE, H.: A Syndrome Produced by Diverse Nocuous Agents. *Nature*, 138:32, 1936.

8. SELYE, H.: Thymus and Adrenals in the Response of the Organism to Injuries and Intoxications. *Brit. Jour. Exper. Path.*, 17:234, 1936.

9. SELYE, H.: The General Adaptation Syndrome and the Diseases of Adaptation. *Jour. Clin. Endocrinol.*, 6:117, 1946.

10. SELYE, H., and COLLIP, J. B.: Fundamental Factors in the Interpretation of Stimuli Influencing Endocrine Glands. *Endocrinol.*, 20:667, 1936.

11. SELYE, H.: Studies on Adaptation. *Endocrinol.*, 21:169, 1937.

12. SELYE, H., and PENTZ, I.: Pathogenic Correlations Between Periarteritis Nodosa, Renal Hypertension and Rheumatic Lesions. *Can. M.A. Jour.*, 49:264, 1943.

13. SELYE, S.; SYLVESTER, O.; HALL, C. E., and LEBLOND, C. P.: Hormonal Production of Arthritis. *Jour. A.M.A.*, 124:201, 1944.

14. SELYE, H.: On the Production of Malignant Hypertension by Chronic Exposure to Various Damaging Agents. *Rev. Can. de Biol.*, 2: 501, 1943.

15. SIMPSON, S. A.; TAIT, J. F.; WEITSTEIN, A.; NEHER, R.; EUW, J. V., and REICHSTEIN, T.: Isolierung Eines Neuen Kristallisierten Hormons aus Nebennieren mit Besonders Hoher Wirksamkeit auf den Mineralatoffwachse. *Experientia.*, 9:333, 1953.

16. SELYE, H.: Correlation Between the Chemical Structure and the Pharmacological Actions of the Steroids. *Endocrinol.*, 30:437, 1942.

17. SELYE, H.: Further Studies Concerning the Participation of the Adrenal Cortex in the Pathogenesis of Arthritis. *Brit. Med. Jour.*, 2:1129, 1949.

18. SELYE, H.: Effect of ACTH and Cortisone Upon an Anaphylactoid Reaction. *Can. Med. Assoc. Jour.*, 61:553, 1949.

19. SELYE, H.: Rôle of the Hypophysis in the Pathogenesis of the Diseases of Adaptation. *Can. Med. Assoc. Jour.*, 50:426, 1944.

20. SELYE, H.: The Rôle of Somatotrophic Hormone (STH) in the Production of Malignant Nephrosclerosis. Periarteritis. Nodosa and Hypertensive Disease. *Brit. Med. Jour.*, p. 263, Feb. 10, 1951.

21. SELYE, H.: The Influence of STH, ACTH, and Cortisone Upon Resistance to Infection. *Can. Med. Assoc. Jour.*, 64:489, 1951.

22. LEMONDE, P.; PANISSET, M.; DOBIJA, M., and SELYE, H.: Protection by Somatotrophic Hormone (STH) Against Experimental Tuberculosis. *Jour. Clin. Endocrinol. and Metabol.*, 12:973, 1952.

23. LEMONDE, P.; PANISSET, M.; DOBIJA, M., and SELYE, H.: Influence de la Somatotrophine sur la Tuberculose Expérimentale Chez le Rat et la Souris. *Ann. Endocrinol.*, 13:897, 1952.

24. INGLE, D. J.: III. Hormones and Metabolism. Parameters of Metabolic Problems. In: Recent Progress in Hormone Research VI, 159, *Academic Press., Inc.*, Publ., New York, 1951.

25. SELYE, H.: The Local Adaptation Syndrome (L-A-S). *XIX Congr. Internat. Physiol.*, Aug., 31 - Sept. 4, p. 750, Montréal, 1953.

26. SELYE, H.: On the Mechanism Through Which Hydrocortisone Affects the Resistance of Tissues to Injury (An Experimental Study with the Granuloma-Pouch Technique"). *Jour. A.M.A.*, 152:1207, 1953.

27. HECHTER, O.: The Adrenocortical Secretory Product: An International Symposium—The Mechanism of Inflammation—JASMIN, G., and ROBERT, A., (Ed.) *Acta, Inc.*, p. 21, Montreal, 1953.

Acknowledgment: The work on which this article is based was supported in part by a grant from the Schering Corporation.

CONGENITAL DYSPHAGIA. NEUROGENIC CONSIDERATIONS.*

SEYMOUR R. COHEN, M.D.,

Los Angeles, Calif.

Dysphagia in newborn infants and very young children presents a complex and frequently challenging diagnostic and therapeutic problem. It is almost always due either to a congenital anatomic deficiency or to a neuropathologic disturbance.

This study was undertaken to outline some neurological causes of dysphagia in newborn infants and very young children. The anatomic deficiencies have been stressed frequently, but, as will be shown in this study, there are also neurological abnormalities which cause dysphagia.

Disturbances of deglutition in infants and newborns have not received as much attention in the literature as have the more urgent and dramatic respiratory emergencies of the neonatal period. Serious impairment in function of the respiratory tract results from any important dysfunction of the swallowing mechanism, not unlike the death-dealing lung disease seen in patients with bulbar paralysis.

It is not uncommon to be consulted for bronchoscopy in newborns with atelectasis in whom the primary disease is actually one of disturbance of deglutition. In infants the respiratory distress may be of such great urgency as to misdirect attention from the primary disease.

It is axiomatic that a normally functioning respiratory tract is necessary for normal feeding in the infant. If the respiratory tract is to function normally, a normal or nearly normal swallowing mechanism is essential. The true overseer of the respiratory tract is the swallowing reflex. Even as in their embryology, the respiratory and upper alimentary

---

* Presented as Candidate's Thesis at the Fifty-Ninth Annual Meeting of the American Largyngological, Rhinological and Otological Society, Inc., Hollywood, Fla., March 15-16, 1955.

Editor's Note: This ms. received in Laryngoscope Office and accepted for publication, February 7, 1955.

tracts are destined to remain together and depend upon each other for physiologic normality. Early diagnosis of the cause of dysphagia is, therefore, essential to prevent, if possible, irreversible pulmonary damage.

REVIEW OF THE NEUROLOGY AND PHYSIOLOGY OF DEGLUTITION.[1,2,3,4]

The swallowing mechanism is considered to be composed of three phases: the buccal-pharyngeal, the esophageal, and the cardio-gastric phases.

The buccal-pharyngeal phase is under voluntary control. The food or liquid is pushed backward upon the dorsum of the tongue and by muscular action of the tongue is rolled backward to lie in front of the fauces. The oral, nasal and laryngeal surfaces are closed by the lips, tongue and soft palate as the larynx moves upward. The myelohyoid muscle contracts and presses the tongue against the hard palate. This movement pushes the bolus downward into the pharynx as the larynx returns to its normal position.

This phase occurs as a reflex action by stimulation of sensory areas which are scattered over the mucosa of the base of the tongue, the soft palate, and the posterior wall of the pharynx. Stimulation of these receptor organs by contact with oral contents causes afferent stimuli to be carried over the glossopharyngeal nerve, the second division of the Vth nerve, and the superior laryngeal nerve to the swallowing center in the floor of the fourth ventricle. Anesthetizing these receptors makes swallowing virtually impossible. Destruction of the central nerves by any neurological disorder involving this area may result in difficulty with swallowing.

The esophageal phase follows reflexly with relaxation of the cricopharyngeal sphincter and the esophagus as a whole. Liquids drop immediately by gravity to the ampullary end. Solids, however, pass by coordinated peristalsis, reaching the distal esophagus at the end of this phase. Even though liquids are thrown down the esophagus without regard to peristalsis, the peristaltic wave which starts at the onset of the esophageal phase continues in its usual manner. Peristalsis, at least over the lower two-thirds of the esopha-

gus, is an autonomous function of the esophagus initiated voluntarily in the pharynx and completed by the intrinsic myenteric plexus. The reflex continues to function normally even after all central nervous connections are severed, as long as the intramural plexuses remain intact.

In humans two wave types are seen. The primary wave travels without interruption toward the distal esophagus and is the propelling force for the bolus. It is initiated by the bucco-pharyngeal phase. The secondary peristaltic wave depends on intra-esophageal distention for adequate stimulation. Studies suggest that stimulation of the vagi causes contraction of the circular muscle bundles and at the same time causes relaxation of the longitudinal muscle bundles. Stimulation of the sympathetics appears to produce just the opposite reaction.

The cardio-gastric phase begins as swallowed material reaches the ampulla. Here, there is a pause and a change in the rhythm as the closing mechanism of the esophagus, just proximal to the stomach, relaxes in quick periods to permit gushes of food to enter the stomach. At the cardia there appears to be a rhythmic mechanism for emptying of the ampulla.

The diaphragm appears to have little or no control except that on deep inspiration there is a temporary slowing of the flow of the food into the stomach. There is a very fine correlation between normal peristaltic activity and the release of the closing mechanism at the cardia. The tone of the cardia is inhibited by mild stimulation of the gastric mucosa, and by sensory impulses arising in the mouth and the pharynx. Its tone increases as digestion proceeds. Any local irritation at the cardia produces hypotonicity. The vagus is responsible for a degree of tone at the cardia, at least in the normal resting terminal esophagus. Sympathetic stimulation invariably causes contraction of the ampullary end of the esophagus. The vagus increases the tonicity of the esophagus at the same time as it relaxes the cardiac end.

The origin of the sympathetic supply to the esophagus is in the superior and inferior cervical sympathetic ganglia. The former getting its branches from the first to the fourth

cervical levels, and the latter largely from the seventh and eighth cervical levels. These fibers form a plexus as they join the esophagus organ. Within the chest, filaments are supplied by the fourth and fifth thoracic levels and by the preganglionic fibers of both the greater and lesser splanchnic nerves. The greater splanchnic nerve gets its fibers from the fifth to the ninth thoracic levels, and the lesser gets its fibers from the ninth and tenth thoracic levels. The abdominal segment receives filaments bilaterally from the celiac plexus, and a few fibers from the sympathetic plexus surrounding the left gastric and inferior phrenic arteries.

The parasympathetic arises from both vagus nerves which are intimately associated, both anatomically and functionally, with the esophagus. The vagi emerge from their pulmonary plexus behind the right and left lung roots and divide into several branches and become arranged along the anterior and posterior surfaces as the complicated net of the esophageal plexuses. The left passes anteriorly, and the right swings posteriorly, each with branches from the other forming the anterior and posterior plexuses. The plexuses cover most of the lower half of the esophagus, but soon differentiate again and emerge toward their distal portion. The left remains anteriorly and the right posteriorly, and they continue closely applied to the esophagus as it proceeds through the diaphragmatic hiatus. The recurrent laryngeal nerve gives off several esophageal branches.

The intrinsic nerve plexuses consisting of Meissner's and Auerbach's plexuses are comparable with those found elsewhere in the gastrointestinal tract. Auerbach's plexus lies between the inner circular and outer longitudinal muscle layers. It is in this plexus that the vagal fibers end. The other portion of the intrinsic nervous mechanism is Meissner's plexus which makes connections with the myenteric plexus and is found in the sub-mucosal area of the esophagus.

REVIEW OF THE LITERATURE.

Peiper,[5] in 1942, studied newborn infants with respiratory and swallowing difficulties and concluded that these were due to immaturity of the medullary centers.

Macaulay,[6] in 1951, reported a case of a 10-day-old infant with respiratory and swallowing difficulty for a period of 21 days. This apparently was due to head trauma with bruising and edema of the medulla. He felt that there was a defective closure mechanism of the larynx during deglutition.

Otell and Coe[7] point out that paralysis of the esophagus is not a rare condition.

Christie,[8] in 1932, described a case of chronic progressive bulbar palsy, and points to the fact that the roentgenologist is often in a position to direct attention toward the possibility of a neuromuscular lesion. He described the X-ray appearance of paralysis of the esophagus.

Quincke, quoted by Otell and Coe,[7] reported a case of laryngeal ptosis causing dysphagia which was actually a condition of relaxation of the laryngeal musculature.

Hurst,[9] felt that in the Plummer-Vinson syndrome the pharyngoesophageal sphincter, which is normally closed, does not relax after the food has been propelled into the pharynx by the tongue, and thus results in retention of food in the posterior pharynx. There is no abnormality in the esophagus associated with this syndrome.

Riley,[10] in 1952, reported 33 cases of a syndrome which is characterized by evidence of vegetative dysfunction with excessive perspiration, drooling, erythematous blotching of the skin, intermittent hypertension, defective lacrimation, hyporeflexia, and emotional instability. All the patients with the complete syndrome were Hebrew. No specific neurological abnormality was demonstrated. Cyclic vomiting and frequent pulmonary infections occurred in 23 of the group of 33. The problem began at an early age. Cystic fibrosis of the pancreas was suspected because of the frequency of pulmonary infection. Some had mental retardation, and in about half of the patients convulsions were present. There seemed to be a familial predisposition. Postmortem examinations revealed aspiration pneumonitis in two cases without any specific pathology in the central nervous system. He does not stress the swallowing difficulty these children may have.

Albanese,[11] in 1949, reviewed the pathology and histology

of amyotonia congenita. The muscles show degenerative changes secondary to defective innervation. Muscle fibers are hypertrophied. Some are normal in size and consistency, but many were small or hypoplastic. There is no atrophy, merely hypoplasia, of a large portion of the fibers of certain voluntary muscles. The dominant lesions of amyotonia congenita were found in the spinal cord. The anterior horn cells are degenerated and reduced in number.

Allen,[12] stated that cardio-esophageal relaxation refers to total anatomical and physiological incompetence of the distal esophageal segment. He used atropine and roentgenologically was able to demonstrate a prominent sphincteric action at the cardia.

Palmer[2] points out that in cardio-esophageal relaxation free reflux through the esophagus frequently leads to aspiration pneumonia, and within a few days of birth, severe pulmonary disease may supervene. He also states that relaxation is uncommonly associated with other esophageal disease, and apparently rarely with other congenital anomalies.

Neuhauser and Berenberg,[13] in 1947 had one case of cardio-esophageal relaxation associated with an esophageal hemangioma. They felt that spontaneous recovery within two to five months can be expected, and that cardio-esophageal relaxation of the newborn is a self-limited anomaly.

Penner and Druckerman,[14] in 1942, reported two cases presenting disturbance in the esophagus with somatic manifestations of Parkinsonism.

Kronecker and Meltzer[15] in 1883, showed that the esophageal phase of deglutition was initiated by stimulation of the superior laryngeal nerve, and it would extend down the entire length of the esophagus even if the segment of the latter was removed if the extrinsic vagal nerve supply was intact.

Meltzer,[16] in 1898, demonstrated that the orderly progress of peristalsis of the esophagus is exclusively of central origin.

Schmidt,[17] in 1939, studied the effect of stimulation of the glossopharyngeal nerves and the vagi, and demonstrated that the state of tone of the distal portion of the esophagus was

influenced by thermal, mechanical and chemical stimulation of the tongue and mouth.

McGibbon and Mather,[18] in 1937, investigated a series of patients with spasm of the esophagus, the youngest of which was eight months of age. They theorized that in children there may be a congenital inferiority of the sympathetic nervous system. Nervous instability is mentioned by other observers.

Olsen, et al.,[19] in 1950, point out that cardiospasm is a nonorganic stenosis of the lowermost portion of the esophagus immediately above its junction with the stomach, and is seldom more than 4 to 6 centimeters long. They feel that diffuse spasm is not to be confused with achalasia.

Holinger, et al.,[20] regard achalasia as a failure of coordination of the neuromuscular mechanism at the cardia which prevents normal passage of food from the esophagus to the stomach. They point out that the condition can develop in the first few months or years of life, and that it can be present in the newborn infant.

Friedberg,[21] in 1950, reported on the status of the esophagus following vagotomy of 31 patients, and concluded that in the human, the effects of vagotomy on the esophagus are of relatively minor significance.

Holinger, et al.,[20] state that with a history of dysphagia, aspiration pneumonia, and difficulty feeding in an infant, suspicion of a congenital esophageal anomaly should be aroused. They emphasize that with postoperative tracheoesophageal fistulas, the development of strictures at the anastomotic site often makes repeated dilatations necessary in order to obtain a functioning lumen.

Gross and Neuhauser,[22] in 1951, discussed the congenital anomalies of vascular origin causing compression of the trachea and esophagus, and point out that with this anomaly there is a mild to moderate hesitation in swallowing, but that the respiratory symptoms tend to be aggravated during deglutition.

PRESENTATION OF CASES AND DISCUSSION.

The cases that were reviewed were too numerous to report in detail; however, certain cases which illustrate the different groups of neurogenic causes of dysphagia are presented in abstract form and are considered under the following headings:

A. Cortical atrophy, hypoplasia and agenesis.

B. Familial autonomic dysfunction.

C. Familial paralysis.

D. Amyotonia congenita.

E. Neurogenic esophageal dysfunction.

A. CORTICAL ATROPHY, HYPOPLASIA AND AGENESIS.

Case 1: F. T., 10-month-old male, first admitted to the Children's Hospital on December 28, 1953. The chief complaints were that the child had been unable to swallow since birth, required tube feedings practically all his life and had periodic episodes of vomiting. He required resuscitation and was in oxygen for about a month following birth. He had convulsive seizures from the first day of life.

Examination revealed an undernourished, underdeveloped, very thin ten-month-old infant. Saliva drooled noticeably from his mouth. He was irritable and had a weak cry. The mandible was hypoplastic. The mouth and oral pharynx appeared small, and there was an absent gag reflex. Examination of the chest revealed transmitted sounds indicative of tracheobronchial moisture. At direct laryngoscopy some difficulty was encountered in exposing the larynx because of micrognathia. The larynx proper was perfectly normal, and there was no impairment of mobility of the vocal cords. There was conspicuous failure of the constrictor muscles of the pharynx to contract.

Neurological consultation revealed hyperactive reflexes almost with spasticity. The child could see and hear normally, and had no impairment of sensations. The impression was cerebral hypoplasia with spastic quadriplegia resulting from neonatal asphyxia.

The child's course in the hospital was unsatisfactory. Feedings attempted by mouth were always aspirated. It was, therefore, necessary to continue tube and gavage feedings. The child was discharged unimproved to be cared for in a home for retarded children.

Case 2: D. B., two-month-old female, first admitted to the Children's Hospital on October 21, 1953. The chief complaints were inability to swallow, and malnutrition. She had never been able to swallow properly, nor to breathe well because of an over-abundance of very thick mucus in the throat, which was first noted immediately after birth. She was a full term normal cephalic delivery. Several formula changes were made, but the child was still unable to swallow.

Examination revealed a poorly nourished, underdeveloped infant. There was a great deal of mucus in the mouth and pharynx with some drooling, but the tongue was dry. She was unable to focus her eyes. Ex-

amination of the chest showed many wheezes and rhonchi transmitted from the throat. Direct laryngoscopy revealed a very slight laryngomalacia which was insufficient to account for the respiratory and swallowing difficulty. There was a great deal of pooling of secretions in the hypopharynx suggesting obstruction. Esophagoscopy showed no evidence of abnormality. The pharynx was seen to constrict in normal fashion without evidence of paralysis.

Neurological examination revealed bulbar paralysis. The reflexes were equal and active, and motor activity was normal. Impression was deficient neural mechanism for swallowing, probably secondary to diffuse hypoplasia of the brain, or specific bulbar aplasia.

X-rays of the esophagus were reported as showing the lipiodol column to pass through the oral cavity and pharynx during deglutition; however, it was then regurgitated into the nasopharynx and nasal fossa. Only a small portion of dye passed into the stomach. The esophagus was seen to be normally distensible and smooth in outline. There were no pathological findings in the stomach or duodenum, and there was no evidence of pyloric obstruction.

Attempts at feeding the child produced an interesting series of events. Although the child made numerous attempts to swallow, the fluid was heard to churn in the hypopharynx and produced choking, followed by cough and regurgitation through the nose. The course in the hospital was unchanged. She continued to have difficulty feeding, and after two and one-half months of hospitalization, the child expired.

Autopsy findings revealed hypoplasia of the brain, broncho-pneumonia and malnutrition. The brain weighed 390 grams (normal 540 grams). There was increased space between the inner surface of the skull and brain, although the sulci and gyri showed no gross abnormalities. Sectioning showed marked diminution in the amount of white matter. The grey matter appeared to be normal, although perhaps slightly increased in thickness. The dorsal portion of the grey matter surrounding the lateral horn showed great discoloration for a distance of 2-3 mm. At the tip of the fourth ventricle there was a small nodule of grey tissue. On sectioning, the brain stained poorly, and there was generalized degeneration of the nuclear elements.

Case 3: (See Fig. 1), P. T., one-month-old female, first admitted to the Children's Hospital on May 28, 1950. The chief complaints were that the child had considerable difficulty swallowing since birth, persistent gagging, and had a great deal of mucus in the mouth and throat, which required suctioning. Because of the extreme difficulty in swallowing, it was necessary to use gavage feeding. This was a first pregnancy, normal delivery. The mother had a history of atypical pneumonia in the second month of pregnancy, and hydramniose and hypertension in the third trimester. At birth the child had considerable generalized edema.

Examination revealed no gross abnormalities. The heart was of normal size and the lung fields were normal.

X-ray of the esophagus revealed a persistent defect in the right side of the esophagus, which was in keeping with an anomalous right subclavian artery. It was assumed that this was the cause of the swallowing difficulty.

On June 7, 1950, the child had a thoracotomy, and a large right anomalous subclavian vessel was found. This was resected and the ductus arteriosus ligated. Following surgery the child did not show any improvement in her ability to swallow. She was discharged on June 17, 1950.

She was readmitted to the hospital on August 3, 1950, for further study.

X-rays of the esophagus, on this admission, revealed no evidence of any obstruction. Esophagoscopy was done, which revealed considerable relaxation and folding of the esophageal walls. There was no evidence of stricture, and no other abnormality was noted. On this admission, however, there were findings of contracted pupils. The pediatric consultant considered this to be due to a paralysis of the cervical sympathetic dilators of the pupils, and it was felt that this was associated with congenital defect in innervation of the esophagus. The child was discharged unim-

Fig. 1. (Case 3) Esophagogram showing a defect in the esophagus due to compression by a large anomalous right subclavian artery. The esophagogram on the right is postoperative. The defect is not seen but there is retention of dye, and slow evacuation.

proved. She was again admitted on September 13, 1950, with suspicion of hypoplasia of the cerebral cortex because her development had not been normal. A pneumoencephalogram showed marked widening of the sulci consistent with cerebral agenesis, and she was discharged unimproved. On June 25, 1951, the child expired.

Autopsy (verbal report of the pathologist) revealed no positive findings in the esophagus, respiratory or gastrointestinal tracts. There was agenesis of the brain of a severe nature.

DISCUSSION.

Transient disorders[6] of the swallowing mechanism may occur in the newborn infant as a result of prematurity, obstruction of the air passages, or from minor bruising or edema of the medullary centers of the brain.

When there is no gross anatomic defect found in a child with persistent dysphagia, neurogenic difficulties should be suspected. These may be due to (*a*) intracranial hemorrhage or edema from trauma, (*b*) brain damage from hypoxia or anoxia, and (*c*) developmental disorders of the central nervous system or its peripheral connections.

Since the behavior of the infant at birth is largely a result of a reflex activity depending on spinal, cerebellar and brain stem centers,[23] it is frequently difficult to evaluate central nervous system development. The early finding of neurogenic difficulty with deglutition may be one of the earliest clinical indications of cerebral hypoplasia or agenesis.

In the first case, neonatal hypoxia was an important factor in producing a widespread neurological disorder. The absent gag reflex, and the failure of the pharyngeal muscles to constrict indicated central disease with paralysis. This differs from the second case in which there was no clinical evidence of paralysis of the pharynx. Here, the child's attempts at swallowing were ineffectual and represented difficulty, undoubtedly due to failure of the normal coordinating mechanism, *i.e.*, abnormality in discharge of coordinated impulses from the swallowing center. This center[1] is in the lower medulla, not precisely localized.

The third case is presented because even though the dysphagia was of the same type as Case 1, there was an associated anomaly (anomalous right subclavian artery) which was presumed to be the cause of the dysphagia. It must be emphasized that anomalies of the great vessels do not produce serious difficulty in swallowing.

B. FAMILIAL AUTONOMIC DYSFUNCTION.

Case 4: (See Figs. 2, 3), S. W., four and one-half-year-old female, first admitted to the Children's Hospital on November 18, 1951. The chief complaints were vomiting, fever, apathy, and listlessness of one day's dura-

Fig. 2.

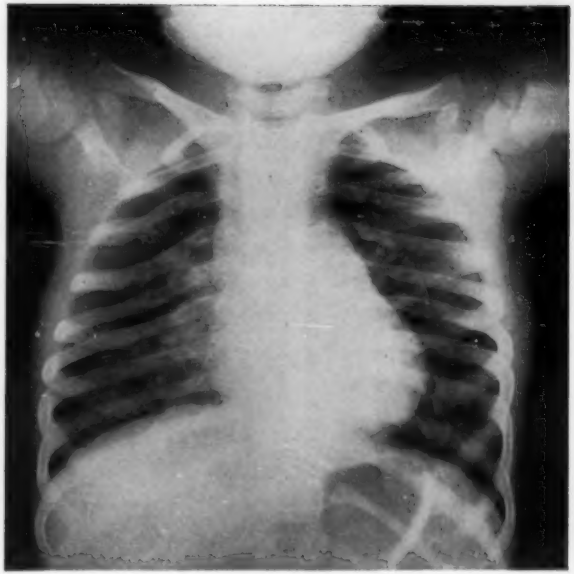

Fig. 3.

Figs. 2 and 3. (Case 4) Shows operative defects in the right 3rd, 4th and 5th ribs posteriorly. Retention of dye in the esophagus due to prolonged emptying time and evidence of aspiration pneumonitis.

tion. The past history was most important. The child had always been a very slow feeder and had gained weight poorly. Since birth, she had choking spells during feedings, when she would gasp and become cyanotic. These symptoms lasted until the age of seven months at which time she developed pneumonia and was seen at an Eastern clinic. In May or June of 1949, despite negative X-ray studies, but because of the very strong suspicion of tracheo-esophageal fistula, thoracotomy was performed, but no pathology was found. The difficulty in feeding persisted and gastrostomy was done.

At the age of two years, oral feedings became possible, although she developed intercurrent bronchial infections. Wheezing was noted after the child drank liquids, but solid foods were taken with less difficulty.

Examination on admission revealed marked muscle flaccidity. There were rhonchi and moisture in the lungs. X-rays showed bronchitis. The child was treated for the febrile reaction which cleared, and she was discharged with a tentative diagnosis of amyotonia congenita. She was readmitted on July 10, 1952, because of recurrence of vomiting. Her general condition had progressed and she was much worse. During feeding, she aspirated and developed marked difficulty in breathing. She was admitted with the diagnosis of aspiration pneumonitis. On this admission, bronchoscopy was required on two occasions in order to remove the aspirated feedings, and to clear the atelectasis. Again, the diagnosis was amyotonia congenita, although a suspicion of some bulbar palsy was considered. She was discharged on July 23, 1952.

On the third admission for febrile reactions with vomiting and difficulty in swallowing, it was noted that there was deficient lacrimation, emotional instability, hyporeflexia, periodic muscular weakness, hypertension, and peripheral vascular collapse, and the diagnosis of Riley-Day syndrome was made. She has had 14 hospital admissions to date all because of repeated acute flare-ups of autonomic disturbances.

X-ray study of the swallowing mechanism was done on November 4, 1953. Report of Dr. Humphrey, "operative defects of the third, fourth and fifth ribs posteriorly, the site of operation for the suspected tracheo-esophageal fistula, is noted. The esophagus is retracted to the right of the usual anatomical position in the upper and mid-dorsal region. During deglutition the dye column proceeds through the pharynx and cervical esophagus promptly, but the transit time is prolonged in the dorsal esophagus. Evacuation of the dye through the cardiac orifices occurs relatively infrequently but more promptly in the erect than in the recumbent position. Reverse peristalsis is evident in the dorsal esophagus. There is no evidence of an anatomic stenosis of the esophageal lumen. Roentgen impression is esophageal motor dysfunction."

Case 5: (See Fig. 4), S. S., six-week-old male, first admitted to the Children's Hospital on April 21, 1952. The chief complaints were recurrent episodes of cyanosis and choking, particularly during feedings. The child is a product of a normal delivery but was premature. The past history is important in that the child had respiratory difficulty associated with difficulty in swallowing immediately after birth. X-rays of the chest on the first day of life showed congenital atelectasis of the right upper lobe. The child had been discharged from another hospital just three or four days prior to his admission to the Children's Hospital. On the day before admission, he had suddenly become very cyanotic, developed severe expiratory respiratory difficulty during feeding. He was admitted with the diagnosis of aspiration pneumonitis.

X-rays of the chest revealed unresolved congenital atelectasis of the right upper lobe. Bronchoscopy was done and a large amount of thick purulent secretions were aspirated from the tracheobronchial tree. There was no anatomic abnormality of the tracheobronchial tree or larynx. Following bronchoscopy, X-rays revealed marked clearing of the atelectasis. Because of the persistent difficulty with swallowing and constant aspiration, a tracheo-esophageal fistula was suspected but could not be demonstrated on X-ray of the esophagus.

Fig. 4. (Case 5) Shows congenital right upper lobe atelectasis, clearing after bronchoscopic aspiration.

The course in the hospital was stormy, and on November 3, 1952, the child had another severe cyanotic episode during feeding, and required emergency bronchoscopy. Following this the lung cleared, and his general condition improved. All the studies attempting to account for the difficulty in swallowing and the continued vomiting with aspiration were negative. Feedings were given by polyethylene tube, and the child was discharged on November 27, 1952, with the diagnosis of feeding problem of undetermined etiology.

He was readmitted on May 5, 1953, at the age of eight months, with the history that he had been on gavage feedings since leaving the hospital. He has, however, begun to take small quantities of solid food with a spoon, although feeding and swallowing has still remained very difficult. On this admission, the chief complaints were abdominal distention, high fever, and vomiting. At this time it was noted that the child had no head control, was areflexic, and was relatively insensitive to pain by pinprick, but was alert. When the child cried there were no tears, and he had excessive diaphoresis. The diagnosis of a familial autonomic dysfunction was then obvious.

DISCUSSION.

This group of patients have been most interesting and extremely difficult from the diagnostic standpoint. The feeding difficulties were of such great moment that in both of the cases the recurrences of pulmonary disease led either to the suspicions of tracheo-esophageal fistulae or some anatomic obstruction. These were not found on intensive clinical investigation.

In the first case in this group, surgery was performed to close a tracheo-esophageal fistula which was not found. In the second case, the recurrence of broncho-pulmonary suppuration led to the strong feeling that this was a constitutional disturbance, such as cystic fibrosis of the pancreas. All other diseases and anomalies had been ruled out. All forms of therapy had failed, and it was only after other symptoms were observed that the true diagnosis became obvious.

An understanding of the mechanism is suggested by the esophageal studies in Case 4 which showed delayed evacuation of the dye medium (lipiodol) in the dorsal and also the ampullary end of the esophagus. This strongly suggests autonomic nervous system disease, which governs the neuromuscular function of the lower two-thirds of the esophagus and cardia. This finding is in keeping with other evidences of generalized autonomic disturbances. Another possible etiology of the defective evacuation of the esophagus will be discussed under Group E.

C. FAMILIAL PARALYSIS (BULBAR).

Case 6: (See Fig. 5), L. A., two-week-old female, first admitted to the Children's Hospital on June 3, 1954. The chief complaint was cyanosis due to excessive mucus in the throat immediately after birth. She had been unable to feed because of difficulty in swallowing with choking, and had been fed by gavage. She was transferred to the Children's Hospital for study of the suspected paralysis of the throat. She is the product of a full term, normal delivery.

Examination revealed an active infant whose cry was hoarse, but there was no stridor. There was an excessive amount of mucus in the pharynx and in the mouth. The palate was high and did not move well. There was a very marked diminution of the gag reflex. The infant appeared to be quite normal except for these findings.

Neurological examination showed that the palate did not elevate spontaneously or reflexly. No other neurological abnormalities were present.

The impression was that this was neither amyotonia nor myasthenia gravis. A congenital local abnormality or a very specific bulbar nuclear aplasia was suspected.

Direct laryngoscopy demonstrated paralysis of the left true cord in the midposition. The esophagus appeared normal but the introitus was wide open as though the crico-pharyngeus were paralyzed.

Developmental clinic consultation showed no marked deviation from the normal at this age.

Fig. 5. (Case 6) Lipiodol swallowed, inadvertently produced aspiration bronchogram showing mechanism of broncho-pulmonary disease in a case of bulbar paralysis.

The course in the hospital has been one of great difficulty from the standpoint of maintaining nutrition. Gavage feedings are taken well, but any attempts at feeding orally cause aspiration pneumonitis. Large amounts of mucus in the oral cavity and hypopharynx require constant nursing. At the writing of this paper, the child is still unable to feed.

X-rays of the esophagus showed that the iodized oil remained in the nasopharynx with slight aspiration into the trachea. The swallowing reflex appeared to be absent, and when oil did pass into the upper esophagus it was carried down by what appeared to be normal peristalsis. There was no evidence of esophageal disease.

Family History: This child is a product of the mother and second husband. The first child, 19 years old, is living and well and is the product of the first husband and mother. He had no swallowing difficulty. The second child is a 15-year-old male who is living and well, but who is small for his age and weighs only sixty pounds. He is a product of the second husband and the mother. At birth this boy had extreme difficulty with swallowing, and was kept in the hospital for many months because of paralysis of the throat. His ability to swallow gradually improved, and since the age of two years apparently had been quite well. There also were two male children, 12 and 7 years of age, who are living and well, and who have no history of swallowing difficulty. One child born nine years ago, and another born five years ago, died shortly after birth because of difficulty with swallowing. They presented a picture similar to the child whose case history is given here. The father had a brother who died of "spasm" in early infancy. No other information about this individual is available.

DISCUSSION.

This case does not actually represent a special category of dysfunction. It is merely presented as a special problem of hereditary dysphagia due to a very specific bulbar dysplasia. There is no evidence of cerebral abnormality in the children of this family. That the problem is not a local defect as in Cases 1, 2 and 3 is evidenced by the fact that the palate, pharynx, vocal cord, and cricopharyngeus are all involved. This is in keeping with the diagnosis of central or nuclear (bulbar) dysphagia.

D. AMYOTONIA CONGENITA.

Case 7: (See Figs. 6, 7), L. P., eight and one-half-month-old female first admitted to the Children's Hospital on July 15, 1952. The chief complaint was difficulty in breathing which started while she was being fed. A few days prior to admission, she choked and became cyanotic and required artificial respiration.

Examination on admission revealed a completely flaccid, atonic, pale infant with rapid and shallow breathing. There was considerable mucus filling the throat and the mouth. The gag reflex was very poor. There was marked deformity of the chest with decreased expansion of the right side. The ribs flared on the left side. The trachea was shifted to the right. There were harsh breath sounds heard over the right side which is flat and dull to percussion. The left side was clear to auscultation, but there was hyper-resonance to percussion. The heart was shifted to the right. The extremities were markedly atonic, areflexic, and the ligaments were very relaxed. The diagnosis was aspiration atelectasis.

X-rays revealed the right lung field to be obscure. The heart was pulled to the right chest suggestive of marked atelectasis. The X-rays revealed marked deficiency of the musculature of both arms suggesting a neuromuscular disorder. The child was bronchoscoped on July 16, 1952. The larynx was normal, and the cords moved normally. There was considerable secretion in the trachea and right bronchial tree. The left bronchial tree was normal. Following bronchoscopy the child's respira-

tory distress cleared, but the general condition remained unchanged. Feedings were given by tube. On July 26, 1952, the chest was normally expanded, and the child's condition was very much improved. On August 8, 1952, following an attempt at feeding by nipple, the child suddenly became dyspneic and cyanotic from aspirated formula. Bronchoscopy

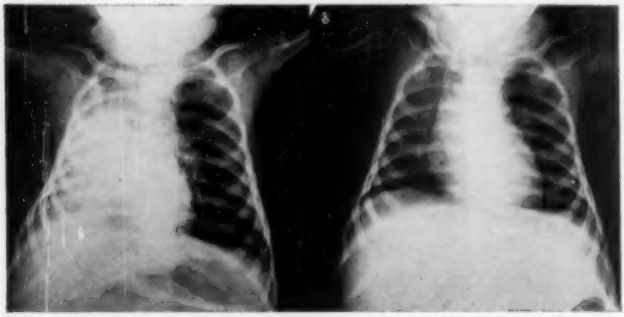

Fig. 6. (Case 7) Showing complete atelectasis of the right lung; and after bronchoscopy, clearing of the right atelectasis and return of mediastinum to normal position.

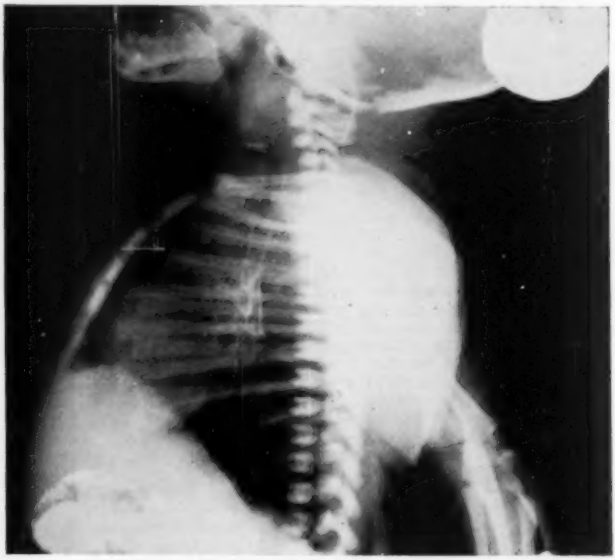

Fig. 7. (Case 7) Showing aspiration on swallowing. All the opaque medium is in the tracheobronchial tree—none in the esophagus.

was done, a large amount of milky secretion was removed from both bronchi, and her condition improved.

Neurological examination revealed an aspiration problem on the basis of bulbar pathology and the diagnosis of amyotonia congenita was made.

On August 9, 1952, the child apparently aspirated her own secretions and expired.

Autopsy confirmed the diagnosis of amyotonia congenita and also the presence of bronchopneumonia and right lower lobe atelectasis due to aspiration.

DISCUSSION.

Children in this group develop their defective swallowing mechanism with progression of their disease. Muscular atony develops and progresses and involves all voluntary musculature. Dysphagia, together with marked weakness of the cough reflex, causes recurrent attacks of aspiration pneumonitis, just as it does in bulbar poliomyelitis.

In reviewing all of the cases of amyotonia congenita which came to autopsy at the Children's Hospital, the chief cause of death was pulmonary disease with obstruction to the tracheobronchial tree from aspiration of feedings.

E. NEUROGENIC ESOPHAGEAL DYSFUNCTION.

Case 8: (See Fig. 8), S. F., six-month-old male, first admitted to the Children's Hospital on March 11, 1949. The chief complaints were gagging on feeding, and vomiting spells.

Examination was essentially negative except for evidence of dehydration.

Barium X-rays showed the esophagus to be very dilated. The barium ran out of the lower end of the esophagus at the same speed as it entered. The form and function noted on X-ray resembled cardiospasm.

The child was discharged on March 18, 1949, to be followed by his physician for a trial of medical treatment. He was admitted again on October 4, 1949, because he had continued to vomit. A Heineke-Mickulicz plastic type operation was performed, and he was discharged on November 9, 1949, in good condition. He was readmitted on November 20, 1950, with the diagnosis of stricture of the esophagus with the complaint of continued dysphagia. Esophageal dilatations for correction of postoperative esophageal stenosis had been done in this child without benefit.

On November 22, 1950, esophago-gastrostomy was done, and the child was discharged on December 2, 1950. He was readmitted on February 11, 1951, because of hematemesis. Esophagoscopy revealed no cause for the bleeding. He has since been readmitted on numerous occasions because of bleeding, and has required transfusions. These episodes of bleeding have spontaneously subsided.

At this writing, the child is reported to have only moderate swallowing difficulty. A postoperative X-ray of the esophagus revealed marked reflux of gastric contents up the esophagus through the anastomosis.

Case 9: (See Fig. 9), A. C., three-month-old female, first admitted to the Children's Hospital on November 8, 1952. The chief complaints were difficulty in feeding since birth associated with choking and vomiting. The child had been discharged from the hospital three days after delivery to

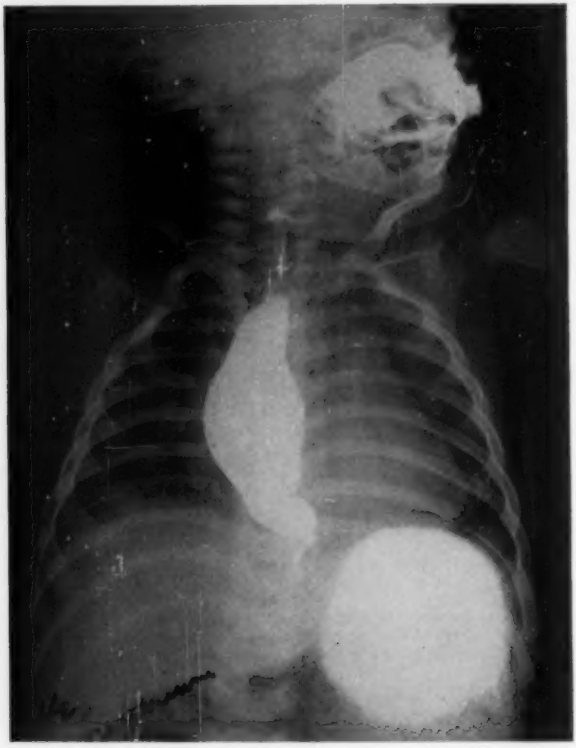

Fig. 8. (Case 8) Showing marked dilatation of the esophagus, retention of barium. Spasm of lower end of esophagus in cardiospasm.

be fed by dropper. She could take about one-half ounce of formula in this manner after which she would choke and begin to vomit. She lost weight rapidly and was admitted to another hospital, where she was tube fed for approximately two and one-half months.

On admission to Children's Hospital, examination revealed cleft palate, deformed cartilage of the ears, inability to hold the head erect, and out-

ward deviation of the left eye. The lower jaw was underdeveloped. The chest was clear to percussion and auscultation except for rhonchi which were transmitted from the throat. Neurologically the child was normal except for poor muscle tone. The diagnosis was Pierre-Robin syndrome with feeding problem.

X-ray studies revealed no evidence of obstruction in the esophagus or stomach. Reflux of gastric contents occurred readily through a patulous cardiac orifice. Esophageal reflux occurred for the most part during inspiration and during forced expiration when the child strained or cried.

Fig. 9. (Case 9) Chalasia—showing marked tortuosity and widening of the esophagus with reflux through a wide open cardia.

Retention of gas and fluid in the dilated and tortuous esophagus was abnormally prolonged. Propulsive activity was evident in the esophagus with the patient in a horizontal position. The lumen contracted to a normal caliber and the esophageal contents were evacuated into the stomach and subsequently into the duodenum without delay. A small segment of the gastric fundus herniated through the esophageal hiatus intermittently during forced respirations. There was also evidence of aspiration pneumonia and bilateral cervical ribs.

A glossoplasty was done, at which time the tongue was sutured to the lower lip. Following this, she continued to have difficulty swallowing, but due to the fact that the tongue could not ptose into the pharynx, feeding,

and grasping of the nipple particularly, was made much easier. She has continued to have the same difficulty feeding, but has developed nicely.

Case 10: (See Fig. 10), H. F., 11-year-old female, first admitted to the Children's Hospital in April, 1950. The chief complaint was that this child had always had great difficulty in swallowing since very early infancy. There was always very slow feeding with gagging and frequent vomiting. Many formula changes were made without any effect. Nervousness was considered to be the etiology of her swallowing difficulty. Her development has been normal in every respect with the exception of continued difficulty in swallowing solid foods.

X-ray revealed three inches of spasm of the esophagus in its middle one-third. Drugs failed to cause relaxation, and the esophageal lumen never returned to normal size. No other abnormality was present.

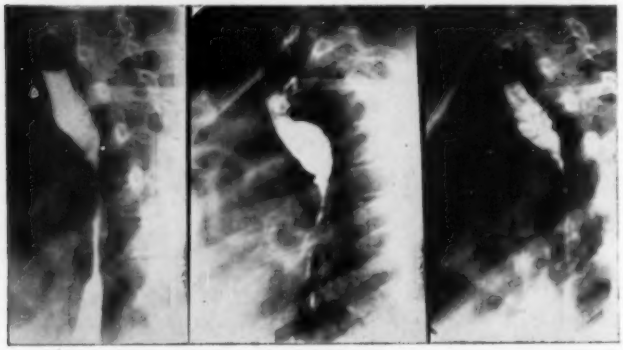

Fig. 10 (Case 10) Demonstrates 3 inches of spasm of the esophagus in its middle one third. The two photographs to the right were taken after relaxing drugs were used without effect.

Esophagoscopy was done, and there was considerable retention in the esophageal lumen. There was great redundancy of the upper one-third of the esophagus with abnormally large folding due to dilatation. In the mid-esophagus a marked degree of spasm was encountered, but the esophagoscope proceeded into the lower third of the esophagus where a small narrowing was noted. This had the appearance of a stricture. Following dilatation the child's ability to swallow improved. The findings were very suggestive of a congenital short esophagus.

She is now 14 years old, and has had repeated dilatations. This is a case of esophageal stricture in a patient with congenital short esophagus with non-sphincteric spasm.

Case 11: (See Fig. 11), C. K., one-day-old male, first admitted to the Children's Hospital on June 23, 1951. The chief complaints were inability to care for his mucus, and dysphagia.

X-rays revealed the esophagus to end in a blind sac with a markedly distended abdomen and excessive gas in the stomach and small bowel. Interpretation was atresia of the esophagus with congenital tracheo-

esophageal fistula. Routine closure of the tracheo-esophageal fistula, and an end-to-end anastomosis of the esophageal segments was performed on June 23, 1951. Surgical exploration revealed the usual type of tracheo-esophageal fistula with a blind upper pouch and the lower segment connected to the trachea. His postoperative condition was good. On July 1, 1951, formula and bubbles were noted to come out of the drain in the chest wound. Methylene blue was given orally, and this came out of the chest wound indicating an esophago-pleural fistula. All feedings were

Fig. 11. (Case 11) Showing stricture at anastomotic site, and tracheo-esophageal fistula which recannulated.

discontinued for a period of a week, and when feedings were again started, the child choked and was considered to have a stricture of the esophagus. Esophageal dilatations were done but the child did poorly, and had numerous episodes of aspiration pneumonitis. He was discharged on August 5, 1951, and readmitted on September 6, 1951, with a recurrent bronchopneumonia and esophageal stenosis.

X-rays of the esophagus with lipiodol taken on October 18, 1951, re-

vealed considerable difficulty in initiating the swallowing mechanism. Lipiodol was noted in the hypopharynx and trachea indicating aspiration, or a recurrent fistula.

On September 25, 1951, a thoracotomy was done, and a recannulated fistula was found and closed. The scar which closed the esophagus almost completely was resected, and the esophago-pleural fistula was closed. Following this operation, the child did much better but continued to have difficulty in swallowing in spite of dilatations, and what appeared to be an adequate esophageal lumen.

Fig. 12. (Case 12) Esophagogram showing reflux of lipiodol into trachea and showing duplicated esophagus ending in blind sac at level of T-3. Delayed emptying time of esophagus was noted, and walls are atonic.

On June 30, 1953, X-rays of the esophagus showed that the lipiodol passed the upper esophagus and the anastomosis without significant delay. Peristaltic activity in the esophagus below the anastomosis was somewhat impaired, which resulted in delayed esophageal empyting. This was more pronounced in the horizontal than in the erect position. The esophagus was retracted to the right, and there was very slight narrowing of the lumen at the level of the anastomosis. The Roentgen impression was esophageal motor dysfunction with impairment in peristaltic activity below the anastomotic site.

Case 12: (See Fig. 12), M. V., three-day-old female, first admitted to the Children's Hospital on August 2, 1954. The chief complaints were difficulty in swallowing, cyanotic episodes on attempting to feed, and a hoarse cry. She was a first child of an uneventful pregnancy and a spontaneous delivery.

Examination revealed congenital atresia of the right ear with deformity of the right auricle. There was a partial paralysis of the right facial nerve involving the lower lip, and a very active gag reflex. There was a loud stridor on inspiration with a moist rattling of mucus in the upper respiratory tract. The voice was somewhat hoarse. The child was unable to swallow without coughing and becoming cyanotic. The mouth and pharynx contained excessive amounts of saliva and mucus secretion. The remainder of the general examination was not abnormal.

X-ray of the chest revealed a right upper lobe atelectasis. X-rays of the esophagus with lipiodol showed a free passage through the esophagus into the stomach. Peristalsis in the esophagus appeared markedly abnormal in that there appeared to be practically no contractibility of the esophagus, and the bolus remained unusually long in the mid-esophagus. No evidence of a tracheo-esophageal fistula was noted. There was bifurcation of the upper esophagus which on the left side ended in a blind pouch. The right side formed the functioning esophagus. The blind pouch ended at the third thoracic vertebral level.

Direct laryngoscopy revealed rotation of the larynx counter clockwise. The true cords appeared normal and the lumen adequate. There were two distinct openings into the esophagus below one on the left taking off near the pyriform sinus, and another to the right posteriorly to the cricoid eminence. There are numerous small tags on the posterior wall of the hypopharynx posterior to the cricoid eminence. These are undoubtedly due to congenital deformities in the development of the larynx.

An exploratory operation was performed on August 17, 1954, at which time no tracheo-esophageal fistula was found. An enterogenous cyst was removed. The child's swallowing difficulty persisted, and she expired on September 1, 1954.

Autopsy findings showed the true cords to be normal. "The cricoid cartilage is deficient posteriorly. A few millimeters to the left of the cricoid cartilage is a 3 mm. opening into a blind pouch which is within the lumen of the esophagus. There is a small opening, measuring 2 mm. in diameter, between the esophagus and the larynx in the area where the cricoid and first tracheal ring are deficient. The fistula is lined by mucosal epithelium. At the level where the trachea arises, there is an accessory trachea which measures 8 cm. in length and which has tracheal cartilage in the wall. This ends in a small glob of what appears to be normal lung tissue (2.5 cm. long by 1 cm. wide). There is no fistula between the accessory trachea and the esophagus. No tracheo-esophageal fistula is present. The normal trachea is normal in size and length, but the cartilages appear crooked and anomalous. The esophagus is a pliable structure with an intact mucosa with the previously mentioned opening into the laryngeal area. The sections appear normal. The brain is normal."

Case 13: (See Fig. 13), L. A., two and one-half-year-old female first admitted to Children's Hospital on June 18, 1954. The chief complaints were difficulty in breathing and feeding. She vomited most of the feedings, and had failed to gain weight. She was a full term, normal delivery. She was reported to have had hoarseness at birth, and was sent home at three days of age. Frequently during feedings, the child stopped breathing, turned blue, coughed and regurgitated. There was no difficulty in breathing except when she was fed.

Examination was negative except that the infant was undernourished and underdeveloped. There was considerable mucus in the hypopharynx. The palate and the pharynx moved normally. Neurological examination was normal. Fluoroscopic examination revealed narrowing of the distal one-third of the esophagus with dilatation of the proximal portion. The

lipiodol passed into the stomach and then refluxed back into the esophagus. It was difficult to tell where the esophagus ended and the stomach began.

On July 19, 1954, esophagoscopy was done and considerable watery mucoid secretion was seen in the upper esophagus indicating retention. The scope passed through the entire length of the esophagus with ease. No stricture or narrowing was seen; however, gastric folds were observed considerably above the diaphragm suggesting a congenitally short esophagus.

The child was discharged, and again admitted on July 25, 1954, with persistent difficulty in swallowing, diarrhea, vomiting and difficulty in breathing. Examination revealed an aspiration bronchopneumonia. On August 3, 1954, X-rays were repeated, and these revealed an esophageal hiatus hernia with short esophagus. There was evidence of esophagitis and ulceration with chalasia.

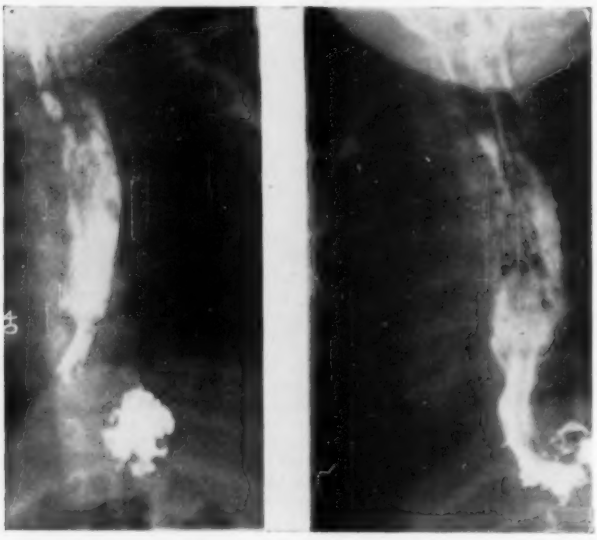

Fig. 13. (Case 12). Case of short esophagus, with thoracic stomach, in which the esophagogram failed to show where esophago-gastric junction is. In the figure on the right, reflux of dye from the stomach is seen.

The child continued to have difficulty swallowing and to lose weight. She expired on August 17, 1954.

Autopsy findings were congenital anomalies of the gastro-intestinal tract, short esophagus, hiatus hernia, thoracic stomach, esophagitis and gastritis. There were also findings of bronchitis, bronchopneumonia and emaciation.

DISCUSSION.

All the cases in this group, with the exception of Case 8, (cardiospasm) had a congenital developmental anomaly of either the respiratory tract, the esophagus, or both. This contradicts the opinions of some writers that chalasia does not occur in association with other anomalies. Our cases of cardio-esophageal relaxation were associated with cerebral agenesis, congenital short esophagus, postoperative cases of cardio-spasm, and a case of laryngo-tracheo-esophageal anomaly.

Of the three cases of short esophagus, two had no evidence of stricture (one case is not reported here); however, these two cases had dysphagia much more severe than one would expect from the presence of a thoracic stomach. The marked prolongation of the evacuation time of the esophagus, without evidence of organic stricture or functional spasm, tends to incriminate the neuromuscular mechanism of the esophagus. The third case showed the presence of non-sphincteric spasm and an organic stricture which probably resulted from the prolonged esophagitis due to reflux of gastric juices through the cardio-esophageal sphincter.

The remaining cases in this group were problems of tracheo-esophageal fistulas. Evidence has accumulated that the severe dysphagia in these cases of tracheo-esophageal fistula is very likely to be partly of neurogenic origin. While it is true that postoperative esophageal stenosis or recannulation of the tracheo-esophageal fistulas will cause severe dysphagia, experience has shown that even when these factors are controlled, troublesome dysphagia persists in many of these infants, and can be demonstrated fluoroscopically.

Eight patients, not reported here, were studied radiographically. In all of these patients, except one, there was delayed emptying of the lower esophageal segment and incoordinated or impaired peristaltic activity .

It is interesting to note that the one patient who had no dysphagia postoperatively had a normal esophagus by X-ray. This patient had a continuity of the muscular coats of the two segments except where the lower segment joined the trachea. The lumen of the upper was not continuous with the lumen of the lower.

It may be theorized that the dysphagia in this group of patients is due to (*a*) congenital abnormality of the intrinsic nerve supply, (*b*) congenital abnormality of the extrinsic nerve supply, or (*c*) surgical disturbance of the esophageal autonomic plexuses during repair of atresias and tracheo-esophageal communications. The effect of a smaller lower segment on the swallowing mechanism still remains unknown.

TREATMENT.

In general, therapy is directed toward maintenance of nutrition, and prevention and treatment of complicating broncho-pulmonary disease.

The respiratory problem is handled by the prevention of aspiration of saliva and feedings by frequent oropharyngeal suctioning, discontinuance of oral feedings, and where necessary, bronchoscopy to relieve obstruction and atelectasis. Tracheotomy may be of benefit in selected cases.

Nutrition may be maintained by parenteral fluids, gavage feedings, or by feedings through an indwelling polyethylene naso-gastric tube.

The position of the patient is important. In cases of bulbar paralysis, a head low position is preferable. The upright position is necessary in those cases where there may be regurgitation from retained food in an esophagus in which there is delayed evacuation, or reflux through an incompetent cardio-esophageal sphincter.

SUMMARY AND CONCLUSIONS.

1. Dysphagia in newborn infants and children produces serious broncho-pulmonary complications.

2. Cases of dysphagia especially related to disturbances of neuro-physiology are presented and discussed under the following headings:

a. Cortical atrophy, hypoplasia and agenesis.

b. Familial autonomic dysfunction.

c. Familial paralysis.

d. Amyotonia congenita.

e. Neurogenic esophageal dysfunction.

3. Transient disorders of deglutition may occur in newborn infants as a result of prematurity, obstruction of the air passages, or from mild intracranial trauma. Persistent dysphagia in a child in whom there is no gross anatomic abnormality should arouse suspicion of a more serious neurogenic cause.

4. The finding of neurogenic dysphagia may be one of the earliest clinical indications of cerebral hypoplasia or agenesis.

5. The persistence of dysphagia in children who have had surgical correction of anomalies indicates the possibility of a defect of innervation.

6. Cases of familial autonomic nervous system disease causing dysphagia are presented.

7. An unusual case of familial bulbar aplasia causing severe dysphagia is reported.

8. Cardio-esophageal relaxation was seen associated with cerebral agenesis, congenital short esophagus, a case of laryngo-tracheo-esophageal anomaly, and postoperatively in a case of cardiospasm.

9. Eight cases of postoperative tracheo-esophageal fistulas not reported here were discussed. Several of these cases showed delayed evacuation of the lower segment of the esophagus and incoordinated peristaltic activity. This suggests that dysphagia in this group is at least in part due to (*a*) congenital abnormality of the intrinsic nerve supply, (*b*) congenital abnormality of the extrinsic nerve supply, or (*c*) surgical disturbance of the esophageal autonomic plexuses during repair of the atresias and tracheo-esophageal communications.

10. Radiographic examination, particularly fluoroscopy, is necessary for diagnosis of defects of neuromuscular function. The use of an indwelling tube through which lipiodol is placed into the esophagus for routine examination is to be discouraged. The swallowing mechanism should be studied in its entirety.

11. The otolaryngologist must be ready to diagnose neuropathological conditions causing dysphagia in addition to diagnosing physical anomalies.

BIBLIOGRAPHY.

1. Krieg, W.J.S.: Functional Neuroanatomy. The Blakiston Company, Philadelphia, 1942.

2. Palmer, E. D.: The Esophagus and Its Diseases. Paul B. Hoeber, Inc., New York, 1952.

3. Best, C. H., and Taylor, N. B.: The Physiological Basis of Medical Practice. The Williams and Wilkins Co., Baltimoree, 1945.

4. Spalteholz, W.: Hand Atlas of Human Anatomy. J. B. Lippincott Co., Phila., 1923.

5. Peiper, A.: Die Schluckstorung. *Montasschrift fur Kinderheilkunde*, 90:37-43, 1942.

6. Macaulay, J. C.: Neuromuscular Incoordination of Swallowing in the Newborn. *Lancet*, 1208-1212, June, 1951.

7. Otell, L. S., and Coe, F. O.: Dysphagia—Roentgenologically Considered. *Amer. Jour. Digest. Dis. and Nutrit.*, 2:117-126, 1935-36.

8. Christie, A. C.: The Roentgen Findings in Chronic, Progressive Bulbar Palsy. *Amer. Jour. Roentgen.*, 27:717-719, 1932.

9. Hurst, A. F.: Some Disorders of the Esophagus. *Jour. Amer. Med. Assoc.*, 102:582-587, 1934.

10. Riley, C.M.: Familial Autonomic Dysfunction. *Jour. Amer. Med. Assoc.*, 149:1532-1535, August, 1952.

11. Albanese, J.T.: Amyotonia Congenita: Report of Two Cases and Discussion. *N. Y. Arch. Pediat.*, 66:411-418, 1949.

12. Allen, R.P.: Cardioesophageal Relaxation: Report of Three Cases. *Radiol.*, 55:214-216, July-Dec., 1950.

13. Neuhauser, E.B., and Berenberg, W.: Cardioesophageal Relaxation As a Cause of Vomiting in Infants. *Radiol.*, 48:480-483, 1947.

14. Penner, A., and Druckerman, L. J.: Segmental Spasm of the Esophagus and Their Relations to Parkinsonism. *Amer. Jour. Digest Dis.*, 9: Sept., 1942.

15. Kronecker, H. and Meltzer, S. J.: Der Schluckmechanismus, seine Erregung und seine Hemmung. *Arch. Anat. Physiol., Supp.* 328-362, 1883.

16. Meltzer, S.J.: On the Cause of Orderly Progress of the Peristaltic Movements in the Esophagus. *Amer. Jour. Phys.*, 2:266-272, March, 1898.

17. Schmidt, H.W.: Diffuse Spasm of the Lower Half of the Esophagus. *Amer. Jour. Digest. Dis.*, 6:693-700, Dec., 1939.

18. McGibbon, J. E. G., and Mather, J. H.: Simple Non-sphincteric Spasm of the Oesophagus. *Lancet*, 1385-1390, June, 1937.

19. Olsen, A.M.; Harrington, S.W.; Moersch, H.J., and Anderson, H.A.: The Treatment of Cardiospasm: Analysis of a Twelve-Year Experience. *Jour. Thorac. Surg.*, 22:164-187, July-Dec., 1950.

20. HOLINGER, P.M.; JOHNSTON, K.C., and POTTS, W.J.: Congenital Anomalies of the Esophagus. *Ann. Otol., Rhinol. and Laryngol.*, 60:707-730, Sept., 1951.

21. FRIEDBERG, S.A.: Observations on the Esophagus Following Vagotomy. *Ann. Otol., Rhinol., and Laryngol.*, 59:751-759, Sept., 1950.

22. GROSS, R.E., and NEUHAUSER, E.B.: Compression of the Trachea or Esophagus by Vascular Anomalies. *Boston Pediat.*, 7:69-83, Jan.-June, 1951.

23. POTTER, E.L.: Pathology of the Fetus and the Newborn. The Year Book Publishers, Inc., Chicago, 1952.

4036 Wilshire Boulevard.

NATIONAL SOCIETY MEETINGS.

Schedule of Meetings for 1956:

Eastern Section. to be held at the Statler Hotel, Boston, Mass., January 13.

Middle Section, to be held at the Netherlands Plaza, Cincinnati, Ohio, January 16.

Western Section, to be held at the County Medical Society Bldg., San Francisco, Calif., January 21.

Southern Section, to be held at the Shamrock, Houston, Texas, January 27-28.

American Board of Otolaryngology, to be held at the Sheraton-Mt. Royal, Montreal, Canada, May 6-11.

American Otological Society, Inc., to be held at the Seigniory Club, Montreal, Canada, May 11-12.

American Laryngological Association to be held at the Seigniory Club, Montreal, Canada, May 13-14.

American Broncho-Esophagological Association, to be held at the Sheraton-Mt. Royal, Montreal, Canada, May 15-16, (afternoons).

The American Laryngological, Rhinological and Otological Society, Inc., will hold its Annual Meeting at the Sheraton-Mt. Royal, Montreal, Canada, May 15-16-17 (mornings only).

Please make early plans to attend the 1956 Spring Meetings in Canada. Both the Seigniory Club and Montreal present most attractive features for you and your family. More information about the places will be told to you.

Reservations at the Sheraton-Mt. Royal Hotel should be made early by addressing the Reservation Supervisor, 1455 Peel Street, Montreal, P. Q., Canada.

PHARYNGOESOPHAGEAL DIVERTICULUM AND THE TECHNIQUE OF ITS SURGICAL TREATMENT.*†

CHEVALIER L. JACKSON, M.D.,

and

CHARLES M. NORRIS, M.D.,

Philadelphia, Pa.

First, a word about terminology: "hypopharyngeal" is a more correct adjective for these diverticula than "pharyngoesophageal" or "esophageal." We really prefer the term "hypopharyngeal diverticula," or "diverticula of the hypopharynx," but the terms "hypopharyngeal," or "esophageal," are so commonly employed that we used the term "pharyngoesophageal diverticulum" in the title of this paper.

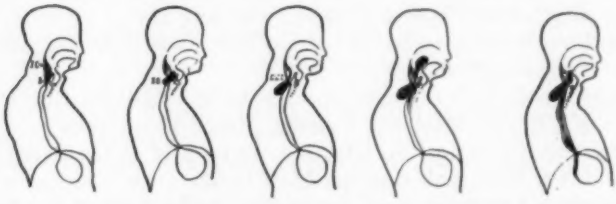

Fig. 1. Schematic drawings showing the progressive enlargement of the common type of pulsion diverticulum of the hypopharynx ("Zenker's") which begins as a herniation of the posterior hypopharyngeal wall, at a congenital weak point in the musculature, known as the space Lannier-Hackerman. (Drawings by Chevalier Jackson.)

Etiology, we are not going to discuss (see Fig. 1). In connection with *symptomatology* and *diagnosis* we will just mention briefly that the obvious symptoms are dysphagia and regurgitation, sometimes of very mild degree. The diagnosis can be made in many cases by attention to the history, or by

---

* Read at the meeting of the Eastern Section of the American Otological, Rhinological and Laryngological Society, Inc., Philadelphia, Jan. 7, 1955.

† From the Department of Laryngology and Bronchoesophagology, Temple University and School of Medicine.

Editor's Note: This ms. received in Laryngoscope Office and accepted for publication, May 23, 1955.

a look at the hypopharynx with the mirror, because these patients practically all have an accumulation of frothy secretions in the pyriform sinuses which can be easily visualized. If you note a little gurgle on squeezing the neck, and see some secretions in one or both pyriform sinuses, the diagnosis is

Fig. 2. Roentgenogram of very large pulsion diverticulum, one of series reported as successfully excised by the one-stage technique (see Fig. 3).

made even before the X-ray is taken. Roentgenray examination is the proper method to establish the diagnosis definitely, and it is important to demonstrate the neck of the sac and to show that the sac empties itself from the upper pole and not through the bottom (see Figs. 2, 3 and 4).

Esophagoscopy is not really absolutely necessary to confirm the diagnosis in most cases. If you have typical X-ray studies

made by a good roentgenologist according to the proper technique, you can be 95 per cent sure that there is not a complicating stenosis or tumor present. To be on the safe side, however, you are prefectly justified in confirming the diagnosis with a preoperative endoscopic examination.

Fig. 3. Photograph of surgical specimen—diverticulum of which preoperative roentgenray appearance is shown in Fig. 2.

TREATMENT.

The earliest treatment advised for diverticulum sounds ridiculous now—surgical drainage. At a later date, dilatation was used. Dilatation may still have a place as a very conservative method in the cases where for some reason excision is contraindicated. By dilatation we mean dilatation of the cricopharyngeal opening. This must, of course, be done with the greatest care, to avoid perforation.

Inversion of the sac has been described and advised, and has been used by some operators with success, the inversion accomplished either by external surgical or by endoscopic

FIG. 4. Antero-posterior and lateral roentgenograms showing clearly (in the lateral projection) the neck of a pulsion diverticulum of the hypopharynx. This is an important diagnostic point—the sac must empty from the upper end; otherwise, the diverticulum is simulated by a dilatation proximal to stenosis.

approach. We feel that the only really sound treatment is surgical amputation through an incision in the neck, and we feel that procedure is so well established now, that it is scarcely worth mentioning the other methods, except from a historical viewpoint.

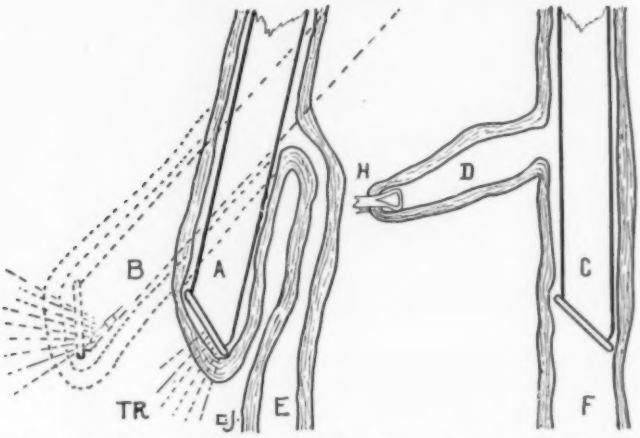

Fig. 5. Schematic diagram of one-stage esophagoscopically guided operation.

We have always been in favor of the one-stage rather than the two-stage operation. The one-stage operation described by Otto Gaub[1] and Chevalier Jackson, then in Pittsburgh (1915), has stood the test of time, and is still good with only minor modifications (see Fig. 5). Among the surgeons who have had large experience and contributed to the development of the technique should be mentioned, Shallow[2,3] and Babcock[4,5] in Philadelphia. Lahey[6,7] of course, was always very much interested in this condition but always preferred the two-stage operation. Perhaps his argument in favor of the two-stage procedure had more foundation in the past than they have today, but since the advent of the antibiotics most operators have come to agree that the one-stage procedure is preferable. Sweet,[8] in Boston, and McNealy,[9] in Chicago, are among those who have contributed to the development of the surgical technique.

CLINICAL EXPERIENCE.

The present paper has as its justification not this sketchy review of the history of the subject, but the very concise presentation of the experience we have had in the past ten years in 75 patients. Of those patients we are reporting on the 53 on whom operation was done.

Of these 53 operated patients, 38 were males and 15 females. It is rather interesting to note the tremendous predominance of males in this series. The average age was 57. I think that is an interesting figure also, because we always think of diverticulum as a condition affecting elderly people. The youngest patients were in their twenties—21 and 27; the oldest was a man of 80, nineteen of them were over 60 and 3 were in their seventies.

The duration of symptoms varied from a few months to many years. Three of our patients had previously been operated upon by others; the remaining 50 were operated upon for the first time. We used a one-stage technique in all but two instances. In these two cases, for certain reasons, the operation was done in two stages.

In most cases we used the esophagoscope in one way or another. We always had it at hand. According to the classic esophagoscopically guided technique, you first introduce the scope into the sac and aspirate its contents, confirming identification by transillumination, and then you withdraw it and pass it into the esophagus, to make sure that you amputate the neck at the proper point without taking off either too much or too little. We did not use the esophagoscope in all cases. In most cases we used it to demonstrate the continuity of the esophagus before amputating the sac. The surgeon with some experience in this particular operation very rarely needs to confirm the identity of the sac by transillumination. The smaller the sac is the more difficult may its identification be, and the more important the aid of the esophagoscope. After you have seen a certain number of diverticula it is generally not difficult to differentiate the pouch from the left lobe of the thyroid gland, but the less experienced operator may mistake that structure for the pouch.

If the esophagoscope is used, the patient should swallow a string a day or two before operation, because when you have a patient on the operating table, regardless of the type of anesthesia used, it is difficult to posture the head and neck just right for introduction of the scope into the subdiverticular esophagus. It is difficult in the presence of a diverticulum anyway, to get a scope into the esophagus, because it always tends to go into the sac.

SURGICAL TECHNIQUE.

We have reviewed the surgical technique as described in the reports of operation in this whole series, and have the following observations to make: For anesthesia we found avertin quite satisfactory previously, but in the past several years we have found intratracheal anesthesia combined with intravenous pentothal much better, and this was the anesthetic used in more than half of our cases. Cervical block has been used in a few cases, and if you have someone to do the cervical block better than the available personnel can do the endotracheal anesthesia, then cervical block should be considered; however, we really find the relaxation that is obtained with endotracheal anesthesia very desirable, and believe it preferable.

The incision we used in most of our cases was a diagonal one, an incision along the anterior border of the left sternomastoid muscle. Some have advocated a transverse incision for cosmetic reasons. We think an incision in the groove anterior to the sternomastoid muscle is just as satisfactory from the cosmetic viewpoint, and gives a little better approach for locating the sac.

If you go down by blunt dissection and locate the omohyoid muscle, always mentioned in descriptions of the surgical approach to the cervical esophagus, though usually thin and of little importance, this muscle is either divided or retracted. As you approach the esophagus by blunt dissection, retracting the left lobe of the thyroid gland medially, you pick up the sac with visceral forceps and draw it out into the wound, freeing it by blunt dissection.

Transillumination with the esophagoscope is the sure proof

that you have located the sac, and has the additional advantage of permitting aspiration of its contents. The esophagoscope is introduced over the string and guide sutures inserted at the upper and lower poles of the sac. After placing those sutures, the scope is withdrawn, because one of the faults found with the esophagoscopically guided technique is that with the scope in the esophagus the neck of the pouch is held deep in the wound, making it difficult to accomplish the amputation and closure. If the scope is withdrawn after

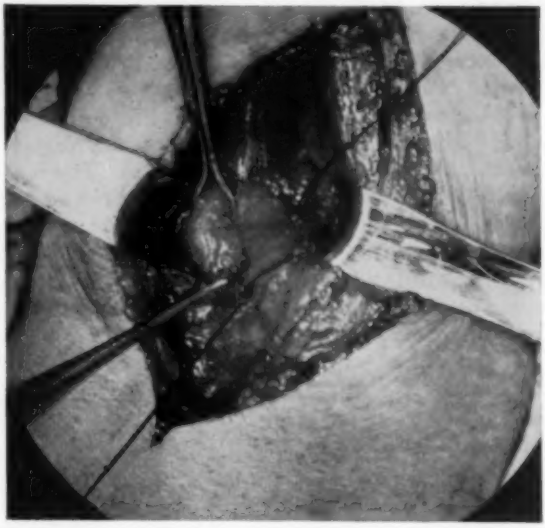

Fig. 6. Single-stage diverticulectomy. The sac is drawn out with visceral forceps and guide sutures of black silk have been placed at the upper and lower margins of its neck. The sac can now be amputated and the neck closed with a follow-up "whipover" suture.

placement of the guide sutures, then the sac can be drawn out in the wound, the neck amputated and the closure performed with ease (see Fig. 6).

Now, as to the technique of this amputation, we have used various methods. We formerly used, almost always, a clamp on the neck of the sac, and did the amputation below that, closing the neck progressively as we continued the amputa-

tion. We have been using the clamp less recently, however, and generally just incise the neck and follow up with a continuous suture of No. 000 chromic catgut on an atraumatic needle.

There has been a good deal of discussion about the proper technique of closure. We find a simple "whipover" stitch very satisfactory, uniting the edges and not necessarily inverting them; the accurate approximation obtained with the use of an atraumatic needle on fine catgut gives a very good closure. Several years ago Furstenberg[10] read a paper on diverticulum before a Sectional meeting of the "Triological" Society, and he contrasted the Cushing type of suture with the whipover suture in closure of the neck, expressing his preference for the whipover. We agree with that, but we do not then make a "pursestring" of it, as Furstenberg describes. The reason we do not make a "pursestring" tie by uniting the ends of the suture at the completion of the closure is that a number of surgeons, McNealy and Sweet among them, have advised against the use of the pursestring closure in this operation. We use a second continuous suture of the same sort, inverting with the second row and then closing over the muscles with interrupted sutures of the same material, introducing a small No. 12 rubber catheter down almost to the line of closure for drainage, and closing the skin with interrupted and continuous sutures of No. 35 alloy steel wire.

POSTOPERATIVE CARE.

The feeding tube is left in place for eight or nine days, checking with barium before it is removed, to see that there is no leakage out into the tissues. If there is such leakage, we wait a few more days before removing the tube. The administration of procaine penicillin, 300,000 units twice a day until the tube is removed, is routine. Tube feedings are given every two hours for the first day or so, consisting of three or four ounces of strained fruit juice, alternated with high protein eggnog.

RESULTS.

In the 53 cases there was one postoperative death; the cause was embolus or cardiac failure, but the last 50 consecutive cases have been without mortality. The average period of hospitalization was 14 days, but six of the patients were out in from 10 to 13 days; several were out in ten days, several in 11 days, and six in between 10 and 13 days. Only seven patients were in the hospital over three weeks. These included the patients operated upon in two stages, and one who developed a flare-up of urinary tract infection that had nothing to do with the diverticulectomy. Three of our patients had been previously operated by others. As we mentioned in the beginning, none of our series have yet required a second operation as far as we know, though several are known to have small residual pouches which are asymptomatic.

COMPLICATIONS.

There was one case of stenosis that required several esophagoscopic dilatations, but now, several years after operation, this patient has no trouble whatever and no persisting stenosis. This was one of the cases in which we did not use esophagoscopic guidance in determining amputation and closure. In six cases there was at least a temporary left recurrent laryngeal paralysis, though several of these have recovered motion of the cord. In one case there was a preoperative left recurrent laryngeal paralysis, possibly due to the diverticulum, possibly to other causes. In one case there was delayed wound infection of no serious consequence (not mediastinal) developing a week or ten days after operation, but subsiding quickly after drainage. As already mentioned, in one case there was a flare-up of urinary tract infection.

In conclusion, a series of 75 cases of diverticulum of the hypopharynx, so-called pharyngoesophageal diverticulum, in 53 of which operation was done by the authors during the past ten years, is reported. The authors believe that their experience reconfirms the value of the one-stage esophagoscopically guided operation.

REFERENCES.

1. GAUB, OTTO, and JACKSON, CHEVALIER: Pulsion Diverticulum of the Esophagus. *Surg., Gynec. and Obstet.*, 21:50, July, 1915.

2. SHALLOW, THOMAS A.: The Treatment of Pharyngeal Diverticula by the Combined One-Stage Closed Method. *Penna. Med. Jour.*, Sept., 1935.

3. JACKSON, CHEVALIER, and SHALLOW, THOMAS A.: Diverticula of the Esophagus; Pulsion, Traction, Malignant and Congenital. *Ann. Surg.*, 83:1, Jan., 1926.

4. BABCOCK, W. WAYNE and JACKSON CHEVALIER: The Single Stage Operation for Pulsion Diverticulum of the Esophagus. *Surg., Gynec. and Obstet.*, 53:667, Nov., 1931.

5. BABCOCK, W. WAYNE and JACKSON, CHEVALIER, L.: The Treatment of Esophageal Diverticulosis. *Trans. Amer. Therap. Soc.*, pp. 50-53, 1936.

6. LAHEY, FRANK H.: The Management of Pulsion Esophageal Diverticulum. *Jour. A.M.A.*, 109:1414, Oct. 30, 1937.

7. LAHEY, FRANK H., and WARREN, KENNETH W.: Esophageal Diverticula. *Surg., Gynec. and Obstet.*, 98:1-28, Jan., 1954.

8. SWEET, RICHARD H.: Pulsion Diverticulum of the Pharyngo-Esophageal Junction; Technique of the One-Stage Operation. *Ann. Surg.*, 125: 41, Jan., 1947.

9. MCNEALY, RAYMOND W., and GLASSMAN, JACOB A.: A One-Stage Pharyngo-esophageal Diverticulectomy. *Surg.*, 21:470, April, 1947.

10. FURSTENBERG, A. C.: Diverticulum of the Esophagus. *Ann. Otol., Rhinol. and Laryngol.*, 56:305, June, 1947.

3401 N. Broad St.

THE SURGICAL TREATMENT OF CANCER OF THE PARANASAL SINUSES.*†

EDGAR L. FRAZELL, M.D.,

New York, N. Y.

Generally speaking—surgery, until recently, has aroused little enthusiasm as the primary or principal method of treatment for cancer of the paranasal sinuses. Such operations have always been considered difficult and fraught with considerable hazard to the patient. Formerly, the operative mortality was high, and complications due to faulty anesthesia, shock, blood loss, and infection were often severe; moreover, surgical attempts at removal of cancer in this region are never entirely satisfactory since, although resection of the entire maxillary antrum is possible, removal of the frontal, ethmoid and sphenoid sinuses is never complete. To many surgeons, the mutilating aspects of such surgery, especially when exenteration of the orbital contents seems indicated, is a deterring factor. In most clinics, therefore, surgery for cancer of the paranasal sinuses has been of the electro-cautery variety and limited to post-irradiation drainage, sequestrectomy, or exposing the area for radium implantation.

Reports in the literature indicate that irradiation, either alone or in combination with surgery, has been the primary treatment method of choice for many years. It was considered less radical and was supposed to circumvent some of the obvious disadvantages of surgery. Since it never completely satisfied these two objectives its choice appears to have been more by default rather than by proved superiority of results. Unfortunately, this method of treatment has serious disadvantages. When delivered in adequate doses, irradiation is prone to produce severe ocular complications which in many instances leads to loss of the eye. Edema of the mucosa of the sinuses plus obstruction of normal drainage channels by in-

* Read at the Fifty-ninth Annual Meeting of The American Laryngological, Rhinological and Otological Society, Inc., Hollywood, Fla., March 16, 1955.

† From the Head and Neck Service, Memorial Hospital, New York City.

Editor's Note: This ms. received in Laryngoscope Office and accepted for publication, June 20, 1955.

fected and necrotic cancer leads to pansinusitis, suppuration, and sepsis; thus, disability is often prolonged for weeks and months. Although destruction of the tumor by irradiation is sometimes complete, the eventual wide surgical drainage and sequestrectomy is often of such magnitude that in many cases radical surgery might as well have been employed initially.

Experiences in our clinic and elsewhere have shown that irradiation, when employed as the sole or chief method of treatment, has produced few cures of cancer of the paranasal sinuses. Vastly improved results, however, have been achieved when irradiation and surgery have been employed together in varying combinations. The most popular of these combinations has been that of heavy external irradiation followed by electro-cautery excision. It is our belief that more emphasis should be placed on surgery initially and that irradiation should be reserved for postoperative use in the advanced unfavorable case or where there is clinical evidence of residual or recurrent disease. Such primary surgery is facilitated by recent improvements in anesthesia, adequate blood replacement and the universal availability of the sulfonamides and antibiotics. Due to these modern surgical aids substantial progress has been made in the surgical attack on these neoplasms during the last two decades, and the reduction in operative mortality and serious complications has been impressive.

The discovery that skin grafting can be successfully employed to cover the operative defect reduces postoperative morbidity and facilitates early application of a satisfactory dental prosthesis.

Meningitis and brain abscess, always a severe threat to the patient in former years, are now rare complications. There is also reason to believe that there has been a significant improvement in the overall salvage rate of patients with cancer of the paranasal sinuses. Many favorable cases are apparently cured by surgery alone while in others more accurate and efficient postoperative irradiation is possible with corresponding diminution of distressing complications.

ANATOMIC CONSIDERATIONS.

Despite the encouragement due to improvements in surgical technique, cancer of the paranasal sinuses remains a highly lethal disease and its treatment is one of the most difficult encountered in the head and neck region. The continued high mortality can be attributed mostly to the complex anatomy of the nasal cavity and accessory sinuses which makes early diagnosis of these neoplasms almost impossible.

Cancer arising in the accessory sinuses is rarely confined to a single set of air cells at the time of diagnosis, so that accurate classification of the exact anatomic site of origin in some cases may be difficult or impossible. In the case of lesions arising in the floor or lateral wall of the antrum, a bulging mass may present in the mouth or cheek so that the probable site of origin may be relatively easy to determine. If the mesial wall of the antrum is involved, erosion of the nasal party wall and extension into the nasal cavity, ethmoid and sphenoid cells and orbit is common. The same degree of involvement may be seen in lesions which are primary in the ethmoid sinuses. It appears that without surgical exploration, the extent and exact origin of tumors of the paranasal sinuses is largely a matter of conjecture. Even at operation, one may be unable to make detailed anatomic classification due to widespread involvement. Classification of these tumors, while desirable in the interest of statistical analysis, accuracy of observations, and prognosis, is of limited value from the surgical viewpoint. Practically speaking, there is little variation in the surgical approach to cancer of the paranasal sinuses and nasal cavity since the basic operation entails resection of the maxilla with curettage of the other sinuses.

Despite the difficulties enumerated, we attempt to classify all tumors of the paranasal sinuses and nasal cavity. In our experience approximately one-third of the cancers of this region apparently arise within the nasal cavity. Tumors, primary in the maxillary antrum, are six or seven times more frequent than those arising in the ethmoid cells. A point of interest is that cancer is rarely demonstrated to have arisen primarily in the frontal or sphenoid sinuses though these air cells are frequently involved secondarily. This is possibly of

some etiological significance since these latter areas show a lessened incidence of inflammatory conditions.

SIGNS AND SYMPTOMS.

Depending upon the anatomic site of origin of the neoplasm, numerous signs and symptoms may be said to be diagnostic of cancer of the paranasal sinuses. These include local pain, swelling over the malar region, lacrimation, displacement of the orbital contents, nasal obstruction and discharge. These symptoms are not peculiar to cancer alone, and it should be pointed out that when associated with cancer of this region, are usually indicative of advanced disease. Cancer of the paranasal sinuses rarely produces serious symptoms in its early stages and is usually apparent only after erosion of bone with extension into the nasal cavity, orbit, or soft parts of the cheek. Confusion with inflammatory conditions may occur since many patients give a history suggesting this diagnosis. Unfortunately, routine radiographic studies may be of limited value in confirming the diagnosis of cancer until late in the course of the disease. The discrepancy between radiographic and surgical findings is often marked, since at operation one commonly finds extensive involvement of more than one of the sinuses in addition to the nasal cavity.

PATHOLOGY.

The paranasal sinuses may be involved either by tumors arising primarily within the air cells themselves or by secondary invasion from tumors originating within the nasal cavity, orbit or mouth. Primary malignant bone tumors of the skull may also encroach on the paranasal sinuses and long-standing and deeply ulcerated skin tumors, on occasion, invade them. Although the diagnostic problems and surgical approach may be essentially the same, the term cancer of the paranasal sinuses, as used in this connection, refers to those tumors arising from the mucous membrane lining these structures. It follows, therefore, that the usual histologic picture of these tumors is that of squamous or epidermoid cancer. The grading may vary from low-grade to highly anaplastic tumors. Adenocarcinoma, when found here, is usually described as adenoidcystic or mucoepidermoid cancer and has its origin in the innumerable minute mucous secreting glands

located in the lining epithelium of the upper air passages. Other less frequent tumors encountered include lymphosarcoma, connective tissue sarcomas, extra-medullary plasmacytomas and melanoma.

OPERATIVE TECHNIQUE.

Once a diagnosis of cancer of the nasal cavity or the paranasal sinuses is established, it is our belief that radical surgical treatment is indicated. Minor procedures such as transnasal polypectomy, lateral rhinotomy and the Caldwell-Luc operation, are inadequate for the treatment of cancer. As previously noted, the extent of the disease is almost invariably

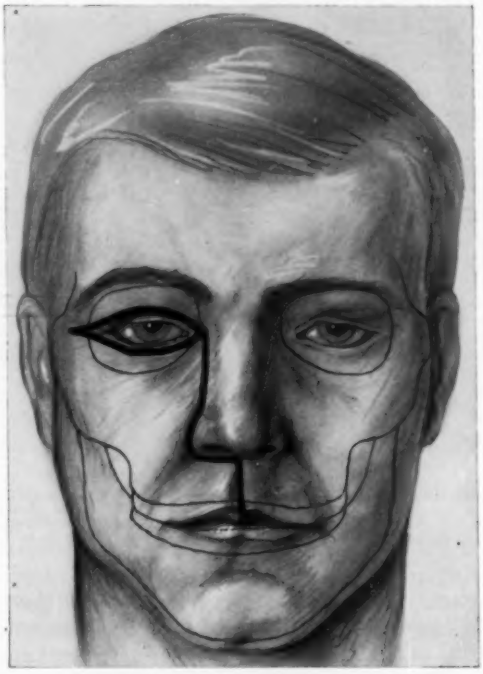

Fig. 1. Resection of the maxillary bone requires wide exposure. The Weber-Fergusson incision is adequate in this respect, and is desirable from the cosmetic point of view. The horizontal limbs of the incision should be placed within a few mms. of the palpebral margins. Should the orbital contents be spared, the upper limb is omitted.

greater than suggested by either clinical signs or radiographic studies. Since this means that the nasal cavity and adjacent sinuses are usually filled with necrotic and infected tumor, wide surgical drainage is in order. This is best accomplished by resection of the maxilla and curettage of the adjacent

Fig. 2. Reflection of the cheek flaps exposes the entire anterior surface of the maxillary antrum and provides direct access to the nasal cavity. The bony attachments are divided by motor driven saw and a hammer and chisel. The saw lessens chances of fracture when the infra-orbital ridge is to be preserved.

areas. Prompt relief from sepsis and pain can thereby be expected. It should be pointed out that routine entry of the frontal sinus is not required due to its infrequent involvement by cancer. The principal steps in the operative treatment of cancer of the paranasal sinuses are best described in the accompanying illustrations.

The question of exenteration of the orbit, as a part of the initial surgical procedure, warrants some discussion. To some, sacrifice of an otherwise normal eye during the course of radical surgical attempt at cure of sinus cancer may seem unnecessarily mutilating. In this connection it should be noted

Fig. 3. Complete resection of the maxilla includes removal of the mesial wall and the structures of the adjacent nasal cavity. This is followed by thorough curettage of the sphenoid and ethmoid sinuses.

that in many cases the eye is ultimately lost as a result of complications of irradiation or extension of the tumor. The decision as to whether or not the eye can be spared is often difficult and in some cases must be delayed until the time of surgery. Should the disease arise in the floor of the maxillary antrum and its principal direction of invasion be downward, preservation of the infraorbital ridge and orbital contents may be practical and relatively safe. Removal of the bony floor of the orbit, however, without removal of the eye may

lead to troublesome diplopia. In those cases where there is obvious destruction of the inferior or mesial walls of the orbit, it is usually in the best interests of the patient to sacrifice the eye. By so doing one may materially increase the margin of excision about the growth and facilitate accurate observation during the postoperative period. Such a clinical setting is usually seen where there is extensive involvement of the ethmoid sinuses.

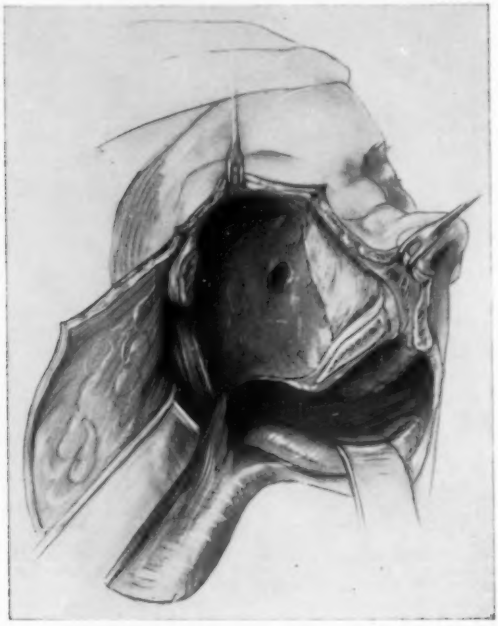

Fig. 4. The entire operative area is lined with a split-thickness graft which is anchored in place with multiple sutures. The cavity is then firmly packed with gauze to provide adequate pressure. The long ends of the sutures (not shown) are useful to tie over and anchor the pack.

Erosion of the base of the skull in the region of the cribriform plates does not necessarily indicate a hopeless prognosis. Portions of this bone are often removed during the course of curettage of the ethmoid area. Although this inevitably results in rents of the dura and leakage of cerebrospinal fluid,

this is no longer considered a major hazard. Meningitis and brain abscess are uncommon complications when sulfonamides, antibiotics and skin grafting are employed.

The discovery that split thickness skin grafts may be successfully used to line the operative defect is, in our opinion, one of the major advances in the surgical treatment of cancer of the paranasal sinuses. If the removal of mucous membrane from the bony surfaces is complete, such grafts have been demonstrated to survive equally well on the cheek flap, bare bone, dura, or cerebral cortex. Such grafts, when reinforced by a firm pack, promptly seal rents of the dura and probably contribute to the low incidence of brain herniation; moreover, in the healed state, they provide a clean and dry cavity which is free of troublesome granulation and polyp formations. Thus early fitting of a dental prosthesis is possible and postoperative morbidity is materially shortened.

PROGNOSIS AND END RESULTS OF TREATMENT.

Since cancer of the paranasal sinuses is rarely diagnosed early, it is uncommon to find the disease confined to a single structure. In the average case, erosion of bone and invasion of neighboring areas is present when the patient first applies for treatment. The disease, therefore, is usually advanced at the time of diagnosis, and the prognosis is largely dependent on the degree and direction of spread. Cancer of the maxillary antrum in which the direction of growth is largely downward or outward with infiltration of the superior alveolus or hard palate, without involvement of other structures, may offer a relatively favorable outlook for radical extirpation and cure. If, on the other hand, the direction of spread is mesialward and superiorly in the direction of the nasal cavity, ethmoids, orbit, base of skull, etc., the prospects of cure by any method of treatment are unfavorable; nevertheless, radical surgery followed by intensive irradiation offers hope for permanent control of the disease in some cases and worthwhile palliation in others. The results of treatment of cancer of the paranasal sinus, regardless of the method of treatment, are often poor and usually mutilating.

Fig. 5. In the healed state the operative incisions are no longer visible. Note the appearance of the skin graft three years following surgery.

The literature contains relatively few reports[1,2,3] of the results of treatment of significant numbers of patients with cancer of the paranasal sinuses. Comparative results of treatment are somewhat difficult to assess since not all reports are based on total experience with the disease. Recent statistics compiled on the Head and Neck Service of the Memorial Hospital[4] indicate a five-year cure rate of 22.5 per cent based on 173 determinate cases treated during the years 1935-

1947. These patients were mostly treated by a combination of surgery and irradiation. Primary emphasis was placed on irradiation, with surgery playing a secondary role, during the earlier years, while more recently this emphasis has been reversed. Patients with epidermoid cancer of the maxillary antrum showed a five-year cure rate of 15.0 per cent when treated principally by irradiation as contrasted to 30.0 per cent five-year cures during the latter years of this experience when surgery was the principal or primary mode of treatment. A similar but less spectacular improvement (20.0 versus 33.0 per cent) was seen in the cures of patients with epidermoid cancer of the ethmoid sinuses. This latter series was small and possibly not statistically significant.

BIBLIOGRAPHY.

1. LARSON, LARS-GUNNAR, and MARTENSSON, GUNNAR: Carcinoma of the Paranasal Sinuses and the Nasal Cavities. *Acta Radiologica*, 42:149-172, 1954.

2. NEW, G. B.: Malignant Disease of the Paranasal Sinuses. *Am. Jour. Surg.*, n. s., 42:170-173, 1938.

3. MARTIN, HAYES: Cancer of the Head and Neck. *Jour. A.M.A.*, 137: 1366-1376, Aug. 14, 1948.

4. LEWIS, JOHN S.: Unpublished Data, 1955.

TWO-MILLION-VOLT RADIATION FOR TREATMENT OF MALIGNANCY OF THE HEAD AND NECK.*

FRANK D. LATHROP, M.D.,†

MAGNUS I. SMEDAL, M.D.‡ (by invitation),

Boston, Mass.,

JOHN G. TRUMP, D.Sc.§ (by invitation),

KENNETH A. WRIGHT, B.A., B.S.§ (by invitation),

and

RICHARD C. GRANKE, B.A.§ (by invitation),

Cambridge, Mass.

This is a preliminary report of the management of malignancy of the head and neck in which the principal method of treatment was radiation with two-million-volt Roentgen rays. It is not a statistical report of five-year survivals because supervoltage radiation therapy of this magnitude was first begun at the Lahey Clinic just over five years ago, and, consequently, there is insufficient material to present such an analysis. This presentation is comprised of 171 patients followed concurrently by the Departments of Radiology and Otolaryngology of The Lahey Clinic from the latter part of 1949 through 1954 (see Table I).

Two-million-volt radiation therapy was administered to the patients comprising this series because the size and extent of the local lesion, or the presence of metastases, was considered to militate against adequate surgical removal, recurrence had taken place following previous surgical excision, the patient desired radiation rather than surgical therapy, or the lesion was one in which the commonly accepted form of treatment is Roentgen therapy. Hodgkin's disease and malignancy of

---

* Read at the Fifty-Ninth Annual Meeting of the American Laryngeal, Rhinological and Otological Society, Hollywood, Fla., March 16, 1955.

† From the Department of Otolaryngology, The Lahey Clinic, Boston, Mass.

‡ From the Department of Radiology, The Lahey Clinic, Boston, Mass.

§ From Massachusetts Institute of Technology, Cambridge, Mass.

Editor's Note: This ms. received in Laryngoscope Office and accepted for publication, March 16, 1955.

the thyroid gland are not included in this study, as the progress of such patients after radiation usually is not followed by an otolaryngologist. Surgical intervention, radiation therapy, or both, prior to treatment by two-million-volt Roentgen rays, had been unsuccessful in 34.5 per cent of the patients.

TABLE I.
MALIGNANCY OF THE HEAD AND NECK.

Year Treated:	1949	1950	1951	1952	1953	1954	Total
No. Patients	7	22	31	35	43	33	171
Alive	4	14	17	18	28	26	107

These patients were treated with X-rays generated at 2 mev. using a Van DeGraaff generator. This radiation is physically equivalent to the Gamma rays of radium and of radioactive cobalt. Their half-value layer is equal to about 13 mm. of copper.

The advantages of using 2 mev. X-rays in comparison to 200 kv. X-rays are as follows: First, the dose necessary to produce a threshold erythema of the skin with 200 kv. X-rays in a single exposure is between 450 and 550 *r*, and with 2 mev. this dose will be between 1400 and 1600 *r*. With 200 kv. X-rays in fractionated doses of 300 *r* daily, the skin erythema dose will be under 1000 *r*, and with 2 mev. X-rays, fractionating at the rate of 300 *r* skin dose daily, the first erythema will occur between 3000 and 4000 *r*. The skin, therefore, with 2 mev. X-rays is a minimal problem. Second, increased penetration with 2 mev. X-rays gives a more effective depth dose. For example, with 200 kv. and a 100 sq. cm. field, the dose 10 cm. deep in tissue will be 32 per cent of the dose at the surface, whereas with 2 mev. X-rays using the same field size, the 10 cm. depth dose at the same 50 cm. target-skin distance will be 52 per cent of the dose at the surface. Third, with increasing voltage there is an increase in X-ray output and a greater tendency for the generated X-rays to be propagated in the forward pattern. This results in a far higher X-ray dosage rate and permits the use of longer treatment distances and shorter treatment times. With the 2 mev. X-ray treatments referred to herein, a 125 cm. target-to-skin distance

was used. The inherently lower scattering of 2 mev. radiation maintains a more sharply defined beam even in depth of tissue, and this high energy radiation is not selectively absorbed in bone, as with conventional radiation.

Both rotational and stationary techniques of irradiation are used. Rotational irradiation may be regarded as the use of an infinite number of cross-firing stationary portals. If a square or rectangular field is rotated, the resultant continuously irradiated volume takes the shape of a cylinder; if the field is round, the resultant irradiated volume is a sphere. The machine is stationary in our set-up, and the patient does the rotating at the slow rate of about one revolution per minute.

The cases of intrinsic laryngeal lesions are treated rotationally with a 4 x 4 cm. field with a resulting 4 cm. cylinder volume of irradiation in tissue centered on the true cords, to a total tumor dose of 6000 *r*.

Patients who have extrinsic laryngeal tumors with or without involved nodes, and those with intrinsic laryngeal tumors with nodes, are treated with a cylinder that includes the entire neck to just below the clavicles for a tumor dose of 6000 *r*. In several cases involving the base of the tongue we have supplemented the primary lesion with a small field to a dose of 7500 *r*. In a few cases of lesions in the floor of the mouth and base of the tongue we have limited irradiation to the primary site when no nodes were present and the grade of malignancy was low. Some have been treated by rotation with resultant cylinders of irradiated areas and some by opposing fields only.

Treatment of the nasopharynx requires two fields: the actual nasopharynx and oropharynx are treated by lateral opposing fields shaped to include the necessary regions of lymphatic drainage; the second part of the field includes the cervical, supraclavicular and superior mediastinal areas in one large field with the radiation being given by opposing anterior and posterior fields. The plane of junction of these two fields is carefully marked and matched, and this junction is protected from overdosage or underdosage by staggering its location by 2 to 3 cm. daily. The dosage for nasopharyngeal tumors is carried to 6000 *r*. Patients with laryngeal and

extralaryngeal involvement receive a minimum of 6000 *r*. As stated previously, in cases in which the tongue is involved we have attempted to give 7500 *r* to the primary tumor if possible.

From the clinician's viewpoint, the most distinctive characteristic of the treatment of malignant tumors of the head and neck with supervoltage radiations of two-million volts as compared to conventional deep Roentgen therapy of 250 to 400 kv. is the relative ease with which the patient tolerates treatment. A number of the patients continued to carry on their work during the major portion or all of the period of treatment when their residence and place of employment were so located that they could take off sufficient time from work each day to receive Roentgen therapy. The reaction of the skin to higher doses of 2000 kv. radiation was considerably less than that observed with conventional deep Roentgen therapy. Only on occasion was a weeping and desquamating Roentgen dermatitis encountered and, when it did occur, it subsided rapidly following completion of the Roentgen therapy. In only one instance, to my knowledge, did radionecrosis of the skin occur. This patient had an epidermoid carcinoma, Grade I, of the external auditory canal and middle ear and had received supervoltage radiation on two occasions approximately 14 months apart.

The reaction of the mucous membrane of the nose, mouth and pharynx to two-million-volt radiation did not appear to be as intense as that commonly observed with conventional deep Roentgen therapy. Ulceration and necrosis were observed not infrequently when the lesion was situated in the tonsil area or the hypopharynx, and probably occurred as a result of a combination of the regression of the lesion, secondary infection, and radiation.

The majority of the patients were able to maintain their nutritional requirements fairly satisfactorily while receiving treatment. Almost all lost weight to some degree, however, which they attributed to decreased appetite because food seemed tasteless, or to increased difficulty in mastication of food as a result of dryness of the mouth and throat. A few patients required hospitalization near the end of their course of Roentgen therapy in order to supplement their caloric intake with intravenous feedings and to obtain relief of pain

on swallowing. This occurred most frequently among those patients who had malignant involvement of the hypopharyngeal region.

When it was found necessary to employ surgery following a single course of radiation therapy in an effort to eradicate persistent or recurrent neoplastic disease, less difficulty was encountered post-operatively. The patient usually withstood the operative procedure better; the time required for the wound to heal, although usually longer than in a patient not exposed to radiation, proceeded in a satisfactory manner and fewer complications developed. This probably was because the nutrition of the patient was better, and the skin reaction was less severe than with conventional deep Roentgen ray therapy. When fistula formation or other evidences of improper healing did develop, they responded quite satisfactorily to additional operative procedures; however, when the patient had received more than one course of Roentgen therapy and when the fields of radiation overlapped to some extent so that some tissue through which the operation was to be performed received more than the usual amount of radiation, less satisfactory healing occurred. Under such circumstances the use of split thickness grafts, delayed rotation flaps or tubed pedicle grafts occasionally were necessary to effect healing of the wound.

There were six patients with malignant disease involving the middle ear in this group of 171 patients (see Table II).

TABLE II.

MALIGNANCY OF THE MIDDLE EAR.

Year Treated:	1949	1950	1951	1952	1953	1954	Total
No. Patients	0	0	2	0	2	2	6
Alive	0	0	1	0	1	2	4

The pathologic diagnosis was epidermoid carcinoma in two, adenocarcinoma in three, and glomus jugularis in one. The glomus jugularis was an extensive neoplasm which blocked the external auditory canal, extended into the neck and involved the mastoid process, the middle ear, and petrous pyramid as well as the immediately adjacent bone of the base of the skull. A neoplastic involvement of this extent when the

common carotid artery cannot be sacrificed is obviously inoperable and, therefore, the patient was treated by supervoltage Roentgen therapy alone. The remaining patients were treated by a combination of surgery and two-million-volt Roentgen rays.

The carcinoma of the external auditory canal and middle ear was thought to have been adequately eradicated by an extensive radical mastoidectomy in the first patient of this latter group, only to have recurrence and extension of the tumor develop within a year, which failed to respond to Roentgen therapy; therefore, the next patient was given supervoltage radiation, administered through a narrow field, as soon as possible after radical mastoidectomy. Metastasis to the parotid lymph nodes was present in approximately one year. Another course of two-million-volt radiation was directed to the area through a larger field. This resulted in extensive radionecrosis which required extensive surgical resection of the necrotic area and plastic surgery to afford skin cover. This unfortunate occurrence had its fortuitous aspect, however, for it suggested to us that wider surgical excision of bone might be desirable from a clinical standpoint; consequently, the remaining patients with carcinoma of the middle ear have been treated by surgical excision of the mastoid process, base of the petrous pyramid, and immediately adjacent squama of the temporal bone commensurate with the disease present.

Four of the six patients with malignant disease of the middle ear are alive. The patient with the extensive glomus jugularis continues to improve clinically, although tumor tissue probably still persists but has remained in abeyance during the past nine months. The remaining three patients had carcinoma of the middle ear with dural involvement and have been clinically free of malignant disease for ten, 23 and 40 months.

Thirty-one patients with malignancy of the nasopharynx have received two-million-volt radiation therapy (see Table III). The pathologic diagnosis was epidermoid carcinoma in 13 patients, undifferentiated carcinoma in five, adenocarcinoma in four, lymphoepithelioma in two, transitional cell carcinoma in one, carcinoma simplex in one, reticulum cell

sarcoma in one, lymphosarcoma in one, fibrosarcoma in one, chordoma in one and malignant chromophobe pituitary adenoma in one. The majority of the patients presented evidence of metastatic disease which, as is well known, all too frequently is the first manifestation of nasopharyngeal malignancy. The commonest location for such metastases is the cervical lymph nodes, and this was true of 18 patients in this group. Erosion of the base of the skull was present in seven patients.

TABLE III.
MALIGNANCY OF THE NASOPHARYNX.

Year Treated:	1949	1950	1951	1952	1953	1954	Total
No. Patients	1	4	7	5	6	8	31
Alive	1	3	3	2	5	6	20

Twenty of the 31 patients are alive and 11 are dead. Seventeen of the 20 patients who are alive are clinically free of disease. One patient has recurrent ulceration of the nasopharynx which may be the result of excessive radiation, since he had been given radiation therapy elsewhere prior to being treated at the clinic. Another presents questionable persistent disease, and the third patient, whose pathologic diagnosis was reticulum cell sarcoma, exhibits persistence and extension of the neoplasm.

Of the 20 patients who are alive, one received supervoltage radiation therapy in 1949, three in 1950, three in 1951, two in 1952, five in 1953, and six in 1954. Five of the 31 patients with malignant disease of the nasopharynx had received radiation therapy in one form or another before they were given two-million-volt Roentgen therapy, and of these two are alive and well although one has recurrent ulceration of the nasopharynx. The remaining three patients are dead. Four of the 31 patients received supervoltage radiation on two occasions and, of these, only one is alive and apparently free of disease. The average survival time of the patients who died was eight months. Only one patient was treated five years ago, and she is alive and clinically free of disease.

Carcinoma of the larynx was present in 42 of the 171 patients in this series (see Table IV). A number of the patients

had been advised to have total laryngectomy but elected to have radiation therapy instead. Ten of the 42 patients had cervical metastases. Surgical excision of the neoplasm with recurrence of the carcinoma before administration of two-million volt radiation therapy had been performed in nine, or 21 per cent, of the 42 patients. Total laryngectomy had been performed in five patients and of these, two subsequently had required radical neck dissection for metastatic disease, which in one instance was bilateral and in the other the disease had recurred. Two patients had unilateral radical neck dissection concomitant with total laryngectomy, and the remaining two patients, who had postcricoidal carcinoma, had been subjected to total laryngectomy, pharyngectomy and unilateral radical neck dissection.

TABLE IV.

MALIGNANCY OF THE LARYNX.

Year Treated:	1949	1950	1951	1952	1953	1954	Total
No. Patients	2	8	8	6	12	6	42
Alive	2	6	7	5	12	6	38*

* Six of these had postradiation surgery.

Two-million-volt Roentgen ray therapy was administered to two patients in 1949, eight in 1950, eight in 1951, six in 1952, 12 in 1953, and six in 1954. Thirty-eight of the 42 patients are alive and four are dead. One of the patients who is alive has radionecrosis of the hypopharynx and persistence of disease following two courses of supervoltage radiation; another has questionable recurrence and six required total laryngectomy following radiation for persistent or recurrent disease. One patient who had radiation for recurrent disease following excision of a postcricoid carcinoma and who does not now exhibit evidence of recurrence, has mild postradiation changes of the spinal cord which do not prevent her working. Thus, 30 patients are alive and without evidence of recurrent disease following two-million-volt radiation treatment of the original lesion or of recurrent disease of the larynx. One patient received treatment in 1949, five patients in 1950, six in 1951, four in 1952, 10 in 1953, and four in 1954. All six patients who required total laryngectomy for recurrent disease following supervoltage radiation are alive and well. The

average survival time of those who died was eight months. Two patients were treated five years ago, and both are alive and without evidence of disease, although one required a total laryngectomy for recurrent disease 56 months after beginning radiation therapy.

For the purpose of this study, all patients who had malignant disease of the floor of the mouth, the tonsil or base of the tongue and the hypopharynx were considered as a group (see Table V). There were no instances of carcinoma of the

TABLE V.

MALIGNANCY OF THE FLOOR OF THE MOUTH, TONGUE, TONSIL OR HYPOPHARYNX.

Year Treated:	1949	1950	1951	1952	1953	1954	Total
No. Patients	4	4	9	16	13	13	59
Alive	1	1	3	4	4	9	22*

* Three of these had postradiation surgery.

anterior third of the tongue among these, and of these patients with malignancy of the tonsil, in almost every instance the immediately adjacent tongue was involved. There were 59 patients in this group: 18, or 30 per cent, had had previous surgical intervention, radiation therapy in one form or another, or both, without success before they were given two-million-volt radiation therapy. The pathological diagnosis was epidermoid carcinoma in 46 patients, squamous cell carcinoma in three, undifferentiated carcinoma in two, fibrosarcoma in two, and in the six remaining cases the diagnosis was adenocarcinoma, lymphosarcoma, reticulum cell sarcoma, rhabdomyosarcoma, mixed epidermoid carcinoma and fibrosarcoma, respectively. Metastases to the cervical lymph glands were present in 34 of the patients.

Two-million-volt radiation therapy was given to four patients in 1949, four in 1950, nine in 1951, 16 in 1952, 13 in 1953, and 13 in 1954. Twenty-two patients were alive at the time of their last report, and 37 were dead. Six patients were operated upon after receiving two-million-volt radiation therapy; the lesion was excised in four, and radical neck dissection was performed in two. Two of the former are alive and without evidence of recurrence, and one of the latter is alive

with a question of persistence of disease. Of the remaining 19 patients who are living, 15 are free of disease, three exhibit persistence of the original lesion and in one, metastasis is still present. Only one of the four patients treated five years ago is alive and without evidence of recurrence. The average survival time of the 37 patients who died was nine and a half months.

Seventeen patients with malignant disease of the nose or paranasal sinuses were treated with two-million-volt radiation (see Table VI). Two patients were treated in 1950, two

TABLE VI.

MALIGNANCY OF THE NOSE AND SINUSES.

Year Treated:	1949	1950	1951	1952	1953	1954	Total
No. Patients	0	2	2	4	7	2	17
Alive	0	0	0	3	3	1	7*

* One of these had postradiation surgery.

in 1951, four in 1952, seven in 1953, and two in 1954. Surgical or radiation therapy, or both, had been employed without success in eight patients, or 47 per cent, before they were given supervoltage radiation. The pathologic diagnosis was epidermoid carcinoma in five patients, carcinoma simplex in three, undifferentiated carcinoma in two, poorly differentiated carcinoma in one, adenocarcinoma in one, anaplastic carcinoma in one, rhabdomyosarcoma in two, angiosarcoma in one, and reticulum cell sarcoma in one. The malignancy was localized to the mucous membrane of the nose in two patients, while the sinuses were involved in the remaining 15 patients. Metastatic disease was present in four of these patients. Only seven of the 17 patients are alive, and none was treated five years ago.

Carotid body tumors occasionally are malignant and cannot be excised, because the common carotid artery cannot be sacrificed. Two patients with carotid body tumor have been treated with two-million-volt radiation (see Table VII). One of these patients previously had a carotid tumor removed, which prevented any possibility of further excision. One patient was treated in 1950, and the other in 1953. Both are

living, the former without evidence of tumor; the latter with a tumor mass which presents no evidence of activity.

TABLE VII.

CAROTID BODY TUMOR.

Year Treated:	1949	1950	1951	1952	1953	1954	Total
No. Patients	0	1	0	0	1	0	2
Alive	0	1	0	0	1	0	2

Neoplasms of the parotid gland are considered to be radioresistant. Thirteen patients with malignant disease of the parotid gland and one patient with extensive, recurrent, mixed tumor of the parotid gland have been exposed to two-million-volt radiation therapy (see Table VIII). All but one patient had previously been subjected to surgical intervention without success on at least one occasion. One patient had biopsy of the tumor mass only. The pathologic diagnosis was adenocarcinoma in five patients, carcinoma simplex in four, epidermoid carcinoma in one, poorly differentiated carcinoma in one, fibrosarcoma in two, and a mixed tumor in one. The last mentioned had failed to be eradicated after numerous operations, and at the time radiation therapy was employed the tumor extended so widely that it was anatomically impossible to effect complete surgical removal.

TABLE VIII.

MALIGNANCY OF THE PAROTID GLAND.

Year Treated:	1949	1950	1951	1952	1953	1954	Total
No. Patients	0	3	3	4	2	2	14
Alive	0	3	3	4	2	2	14

Two-million-volt radiation was administered to three patients in 1950, three in 1951, four in 1952, two in 1953, and two in 1954. All are alive, and 10 present no evidence of persistent or recurrent disease. The remaining four patients exhibit suggestive evidence of persistent disease, but whether or not it is viable cannot be determined. In one patient with carcinoma simplex a Brown-Séquard syndrome developed following radiation, but on last report, 56 months after completion of radiation, there was no evidence of recurrence.

UNIVERSITY OF ILLINOIS ANNUAL ASSEMBLY IN OTOLARYNGOLOGY.

The Department of Otolaryngology, University of Illinois College of Medicine, announces its Annual Assembly of Otolaryngology from September 19 through October 1, 1955. This Assembly will consist of two parts:

Part I — September 19 through September 24, 1955, will be devoted to surgical anatomy of the head and neck, fundamental principles of neck surgery and histopathology of the ear, nose and throat. This week will be under the personal direction of Maurice F. Snitman, M.D.

Part II — September 26 through October 1, 1955, will be devoted entirely to lectures and panel discussion of advancements in otolaryngology. The chairman of this section will be Emaneul M. Skolnik, M.D.

Registration is optional for one or both weeks. For further information, address Dr. Francis L. Lederer, 1853 West Polk St., Chicago 13, Ill.

POST-GRADUATE COURSES AT TEMPLE UNIVERSITY.

The following Post-Graduate Courses to be given in this Department during the current year:

Post-Graduate Course in Broncho-Esophagology, October 17 - 28, 1955.

Post-Graduate Course in Laryngology and Laryngeal Surgery, September 19 - 30, 1955.

These courses are all to be given in the Department of Laryngology and Broncho-esophagology, Temple University Hospital and School of Medicine, under the direction of Dr. Chevalier L. Jackson and Dr. Charles M. Norris. The tuition fee for each course is $250.00. Further information and application blanks can be obtained from Dr. Chevalier L. Jackson, 3401 N. Broad Street, Philadelphia 40, Pennsylvania.

SOUTH CAROLINA SOCIETY OF OPHTHALMOLOGY AND OTOLARYNGOLOGY.

Plans have been completed for a joint meeting of the North Carolina Eye, Ear, Nose and Throat Society and the South Carolina Society of Ophthalmology and Otolaryngology at Columbia, S. C., on September 12, 13, and 14, 1955. Headquarters will be the Columbia Hotel.

The following ophthalmologists will be on the program: Dr. E. W. D. Norton of New York, Dr. Frank Carroll of New York, and Dr. William B. Clark of New Orleans.

A most attractive program has been arranged. For further information address Roderick Macdonald, M.D., Secretary and Treasurer, 330 East Main Street, Rock Hill, S. C.

SOUTH AFRICAN LOGOPEDIC SOCIETY.

The South African Logopedic Society (Society of Speech Therapists) publishes a Journal in May and October of each year. Articles deal with the organic and psychological aspects of speech defects, and include subject matter of interest to the medical and allied professions.

Relevant contributions in the field of otolaryngology are invited.

Subscriptions are 10/– per annum including postage and should be addressed to: The Editor, Journal of the S. A. Logopedic Society, Witwatersrand University, Milner Park, Johannesburg, So. Africa.

THE AMERICAN OTORHINOLOGIC SOCIETY FOR PLASTIC SURGERY, Inc.

A short course on Plastic Surgery of the Head and Neck will be given by The American Otorhinologic Society for Plastic Surgery at the Morrison Hotel, Chicago, Illinois, extending from October 7 to October 9, 1955, inclusive. For details write Dr. Louis J. Feit, 66 Park Avenue, New York, N. Y.

COLBY COLLEGE — AUDIOLOGY FOR INDUSTRY.

Colby College, Waterville, Maine, presents the Third Annual Course in Industrial Deafness, August 7 - 13 inclusive. Objective of the course will be to train personnel in initiating and in conducting conservation hearing programs in noisy industries. Seven full time instructors have been selected from authorities in this field. Class limited to 20 participants.

Registrants will live on the College Campus and the Tuition fee of $200.00 includes board and room. Applications should be made to Mr. William A. Macomber, Director, Division of Adult Education and Extension, Colby College, Waterville. Maine. Frederick Thayer Hill, M.D., Director; Joseph Sataloff, M.D., Assistant Director.

BRONCHOESOPHAGOLOGY COURSE

The next Bronchoesophagology Course to be given by the University of Illinois College of Medicine is scheduled for the period October 24 to November 5, 1955, under the direction of Dr. Paul H. Holinger.

Interested registrants will please write directly to the Department of Otolaryngology, University of Illinois College of Medicine, 1853 West Polk Street, Chicago 12, Illinois.

AMERICAN ACADEMY OF OPHTHALMOLOGY AND OTOLARYNGOLOGY HOME STUDY COURSES.

The 1955-1956 Home Study Courses in the basic sciences related to ophthalmology and otolaryngology, offered as a part of the educational program of the American Academy of Ophthalmology and Otolaryngology, will begin on September 1, and continue for a period of ten months. Detailed information and application forms can be secured from Dr. William L. Benedict, the executive secretary-treasurer of the Academy, 100 First Avenue Building, Rochester, Minnesota. Registrations should be completed before August 15.

DIRECTORY OF OTOLARYNGOLOGIC SOCIETIES.

(Secretaries of the various societies are requested to keep this information up to date).

AMERICAN OTOLOGICAL SOCIETY.

President: Dr. Wm. J. McNally, 1509 Sherbrooke St., West Montreal 25, Canada.
Vice-President: Dr. John R. Lindsay, 950 E. 59th St., Chicago 37, Ill.
Secretary-Treasurer: Dr. Lawrence R. Boies, 90 S. Ninth St., Minneapolis 2, Minn.
Editor-Librarian: Dr. Henry L. Williams, Mayo Clinic, Rochester, Minn.
Meeting: Seigniory Club, Montreal, Canada, May 11-12, 1956.

AMERICAN LARYNGOLOGICAL ASSOCIATION.

President: Bernard J. McMahon, 8230 Forsyth Blvd., Clayton 24, Mo.
First Vice-President: Robert L. Goodale, 330 Dartmouth St., Boston, Mass.
Second Vice-President: Paul H. Holinger, 700 North Michigan Ave., Chicago 11, Ill.
Secretary: Harry P. Schenck, 326 South 19th St., Philadelphia 3, Pa.
Treasurer: Fred W. Nixon, 1027 Rose Building, Cleveland, Ohio.
Librarian, Historian and Editor: Edwin N. Broyles, 1100 North Charles St., Baltimore, Md.
Meeting: Mount Royal Hotel, Montreal, Canada, May, 1956.

AMERICAN LARYNGOLOGICAL, RHINOLOGICAL AND OTOLOGICAL SOCIETY, INC.

President: Dr. Dean M. Lierle, Iowa City, Iowa.
President-Elect: Dr. Percy Ireland, Toronto, Canada.
Secretary: Dr. C. Stewart Nash, 277 Alexander St., Rochester, N. Y.
Meeting: Mount Royal Hotel, Montreal, Canada, May, 1956.

AMERICAN MEDICAL ASSOCIATION, SECTION ON LARYNGOLOGY, OTOLOGY AND RHINOLOGY.

Chairman: John R. Lindsay, M.D., Chicago, Ill.
Vice-Chairman: James W. McLaurin, M.D., Baton Rouge, La.
Secretary: Hugh A. Kuhn, M.D., Hammond, Ind.
Representative to Scientific Exhibit: Walter Heck, M.D., San Francisco, Calif.
Section Delegate: Gordon Harkness, M.D., Davenport, Iowa.
Alternate Delegate: Dean Lierle, M.D., Iowa City, Iowa.

AMERICAN ACADEMY OF OPHTHALMOLOGY AND OTOLARYNGOLOGY.

President: Dr. Algernon B. Reese, 73 East 71st St., New York 21, N. Y.
Executive Secretary: Dr. William L. Benedict, Mayo Clinic, Rochester, Minn.
Meeting: Palmer House, Chicago, Ill., October 9-15, 1955.

AMERICAN BRONCHO-ESOPHAGOLOGICAL ASSOCIATION.

President: Dr. Daniel S. Cunning, 115 East 65th St., New York 21, N. Y.
Secretary: Dr. F. Johnson Putney, 1719 Rittenhouse Square, Philadelphia, Pa.
Meeting: Sheraton Mount Royal Hotel, Montreal, Canada, May 15-16, 1956 (afternoons only).

AMERICAN BOARD OF OTOLARYNGOLOGY.

Meeting: Palmer House, Chicago, Ill., October 2-8, 1955.

at ease... you may put your own mind at ease as well as calm your patient when you prescribe Noludar 'Roche' as a sedative (or in larger dosage, as a hypnotic). There is little danger of habituation or other side effects, because Noludar is not a barbiturate. Available in 50-mg and 200-mg tablets, and in liquid form, 50 mg per teaspoonful.

Noludar'® - brand of methyprylon.

Hoffmann - La Roche Inc
Nutley 10 · N. J.

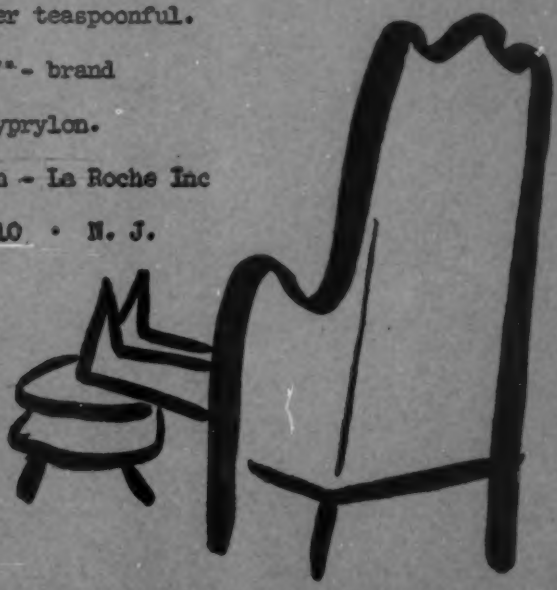

VOLUME LXV JULY, 1955 NUMBER 7

CONTENTS

THE DEVELOPMENT OF THE EPITHELIUM OF THE LARYNX. Eugene S. Hopp, M.D., San Francisco, Calif. - - - - - - - 475

STRESS AND DISEASE. Hans Selye, M.D., Montreal, Canada - - 500

CONGENITAL DYSPHAGIA. NEUROGENIC CONSIDERATIONS. Seymour R. Cohen, M.D., Los Angeles, Calif. - - - - - - - - 515

PHARYNGOESOPHAGEAL DIVERTICULUM AND THE TECHNIQUE OF ITS SURGICAL TREATMENT. Chevalier L. Jackson, M.D., and Charles M. Norris, M.D., Philadelphia, Pa. - - - - - - - 546

THE SURGICAL TREATMENT OF CANCER OF THE PARANASAL SINUSES. Edgar L. Frazell, M.D., New York, N. Y. - - - - - 557

TWO-MILLION-VOLT RADIATION FOR TREATMENT OF MALIGNANCY OF THE HEAD AND NECK. Frank D. Lathrop, M.D.; Magnus I. Smedal, M.D. (by invitation), Boston, Mass.; John G. Trump, D.Sc. (by invitation); Kenneth A. Wright, B.A., B.S. (by invitation), and Richard C. Granke, B.A. (by invitation), Cambridge, Mass. - - - - - - - - - - - - - - - 568

DIRECTORY OF OTOLARYNGOLOGIC SOCIETIES - - - - - - - 582

7

475

500

515

546

557

568

582